

A close-up photograph of a person's hands holding a large, ornate golden trophy cup. The cup has a textured, metallic surface and a wide, flared base. The person's arms are visible, with a tattoo on the left forearm. The background is a bright, out-of-focus sky with soft, circular bokeh light spots.

IFSO World Cup

DISCLOSURES

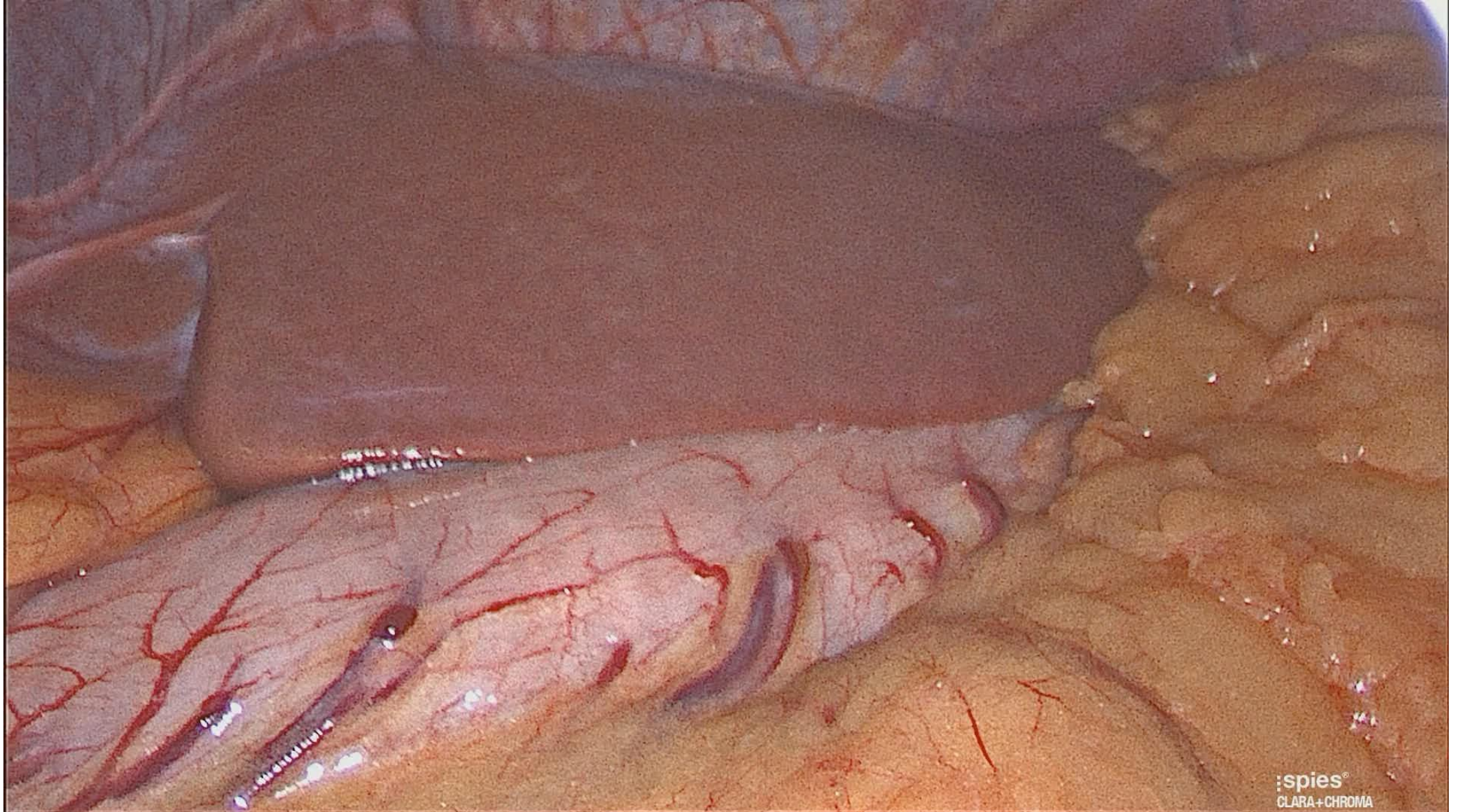
- NONE

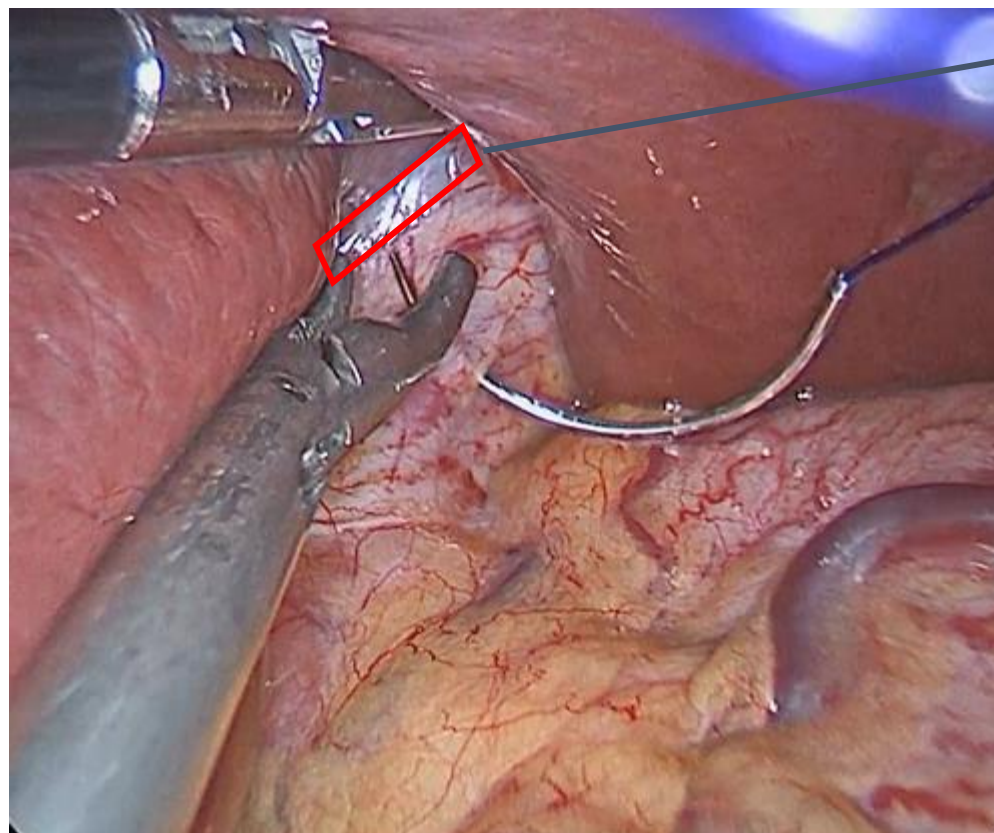
Case Profiles



- 22-yr male
- Height 178cm, Weight 113kg, BMI 35.66 kg/m²
- Obesity (Class II), OSAS (Severe), HH (type 1), Pre-diabetes, MASH

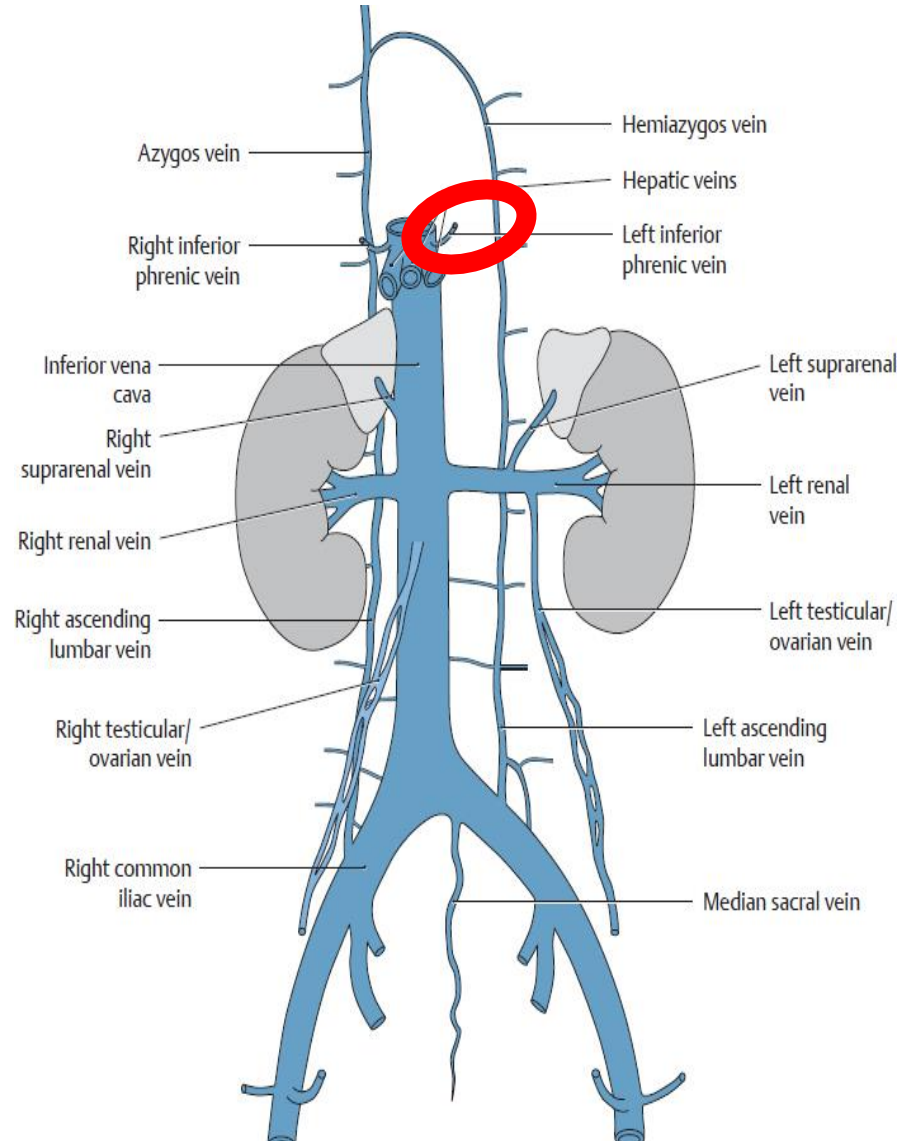
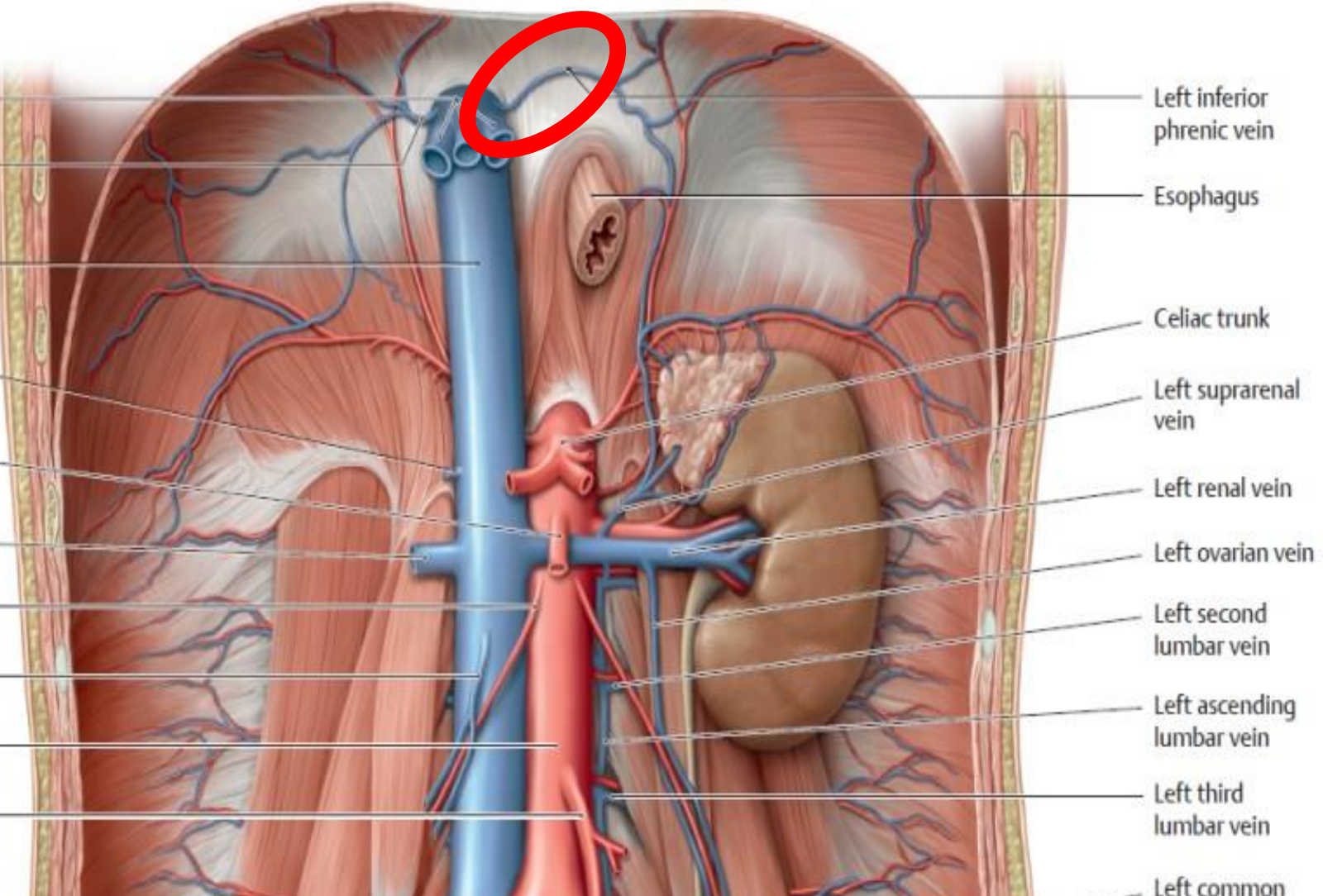
- Planned surgery: Sleeve gastrectomy with HHR





**Left Inferior
Phrenic Vein**

Inferior Phrenic Vein





IFSO

Asia Pacific Chapter