

XXVIII IFSO World Congress

9-12 September 2025 | Santiago, Chile



Complicated Ring-Augmented Procedures
in Bariatric Surgery: A Case Series and
Technical Review.

Mohamed Hany
Medical Research Institute, Alexandria
University, Egypt.

IFSO 2025 Santiago

Combined Therapies, The Dawn of a New Era

ifso2025.org

Disclosure



**XXVIII IFSO
World Congress**

**9-12 September 2025
Santiago, Chile**

- **Nothing to disclose**

History and results of the ring

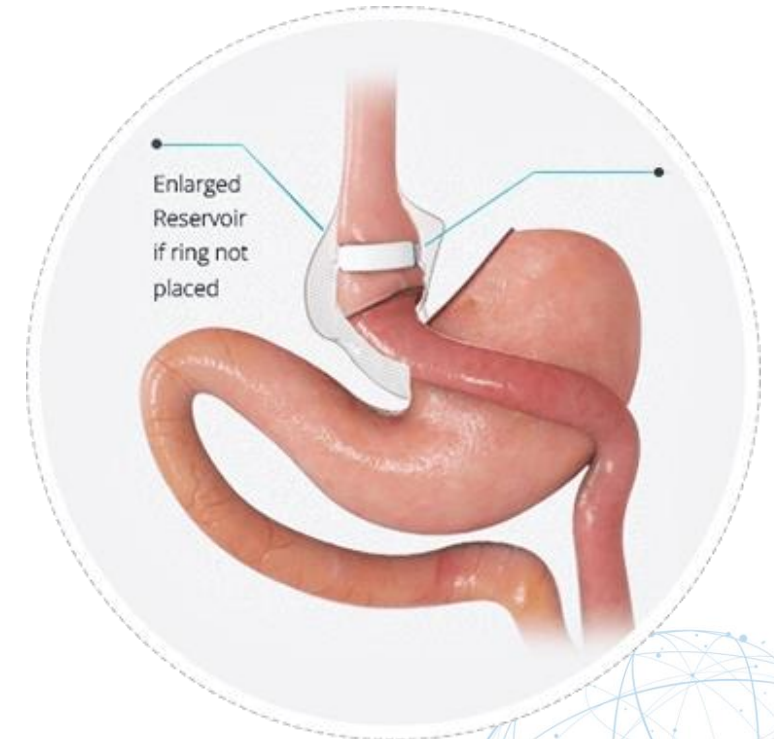
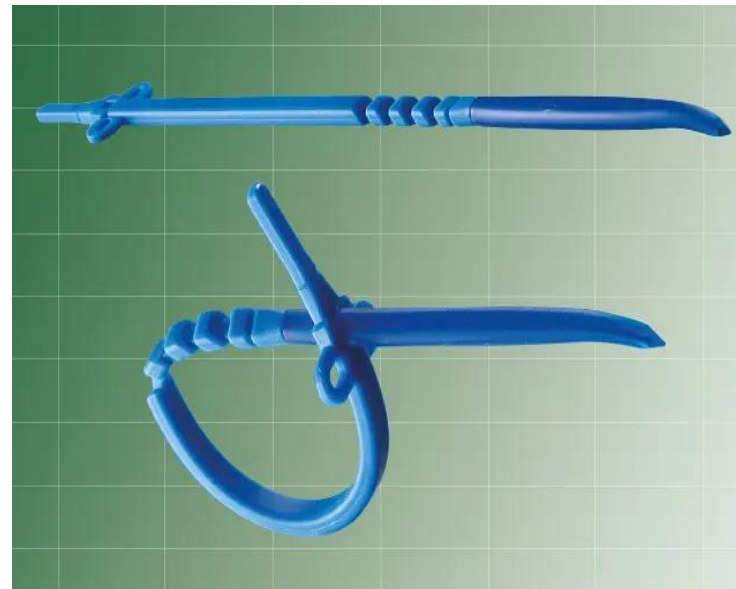
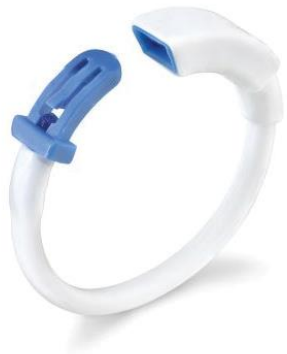
XXVIII IFSO
World Congress

9-12 September 2025
Santiago, Chile

Non-adjustable, non-inflatable ring, which should be positioned loosely around the pouch

Fobi introduced the ring in 1989, aiming to combine the benefits of Roux-en-Y gastric bypass (RYGB) and vertical banded gastroplasty (VBG).



Crampton NA, Izvornikov V, Stubbs RS. Silastic ring gastric bypass: results in 64 patients. *Obes Surg.* 1997 Dec;7(6):489-94. doi: 10.1381/096089297765555232. PMID: 9730506.

Ring-augmented Sleeve Gastrectomy



XXVIII IFSO
World Congress

9-12 September 2025
Santiago, Chile

- RaSG improves long-term weight loss (+6–10% TWL at 3–5 years) and lowers RWG-related revision rates (0.6% vs. 8.3% for SG), with no increase in overall complications [1,2].
- Rings carry a minimal revision/removal risk (7–10%), primarily for regurgitation/reflux/food intolerance, mitigated by larger ring diameter and proximal placement, often requiring removal or adjustment [3].

1. Fink JM, Reutebuch M, Seifert G, Laessle C, Fichtner-Feigl S, Marjanovic G, Fink M. Banded Versus Non-banded Sleeve Gastrectomy: 5-Year Results of a 3-Year Randomized Controlled Trial. *Obes Surg*. 2024 Feb;34(2):310-317. doi: 10.1007/s11695-023-06982-9. Epub 2023 Dec 18. PMID: 38109013; PMCID: PMC10810940.
2. Hany, M., Sabry, A., Torensma, B. *et al.* Comparison of the mid-term outcomes of banded and non-banded sleeve gastrectomy: safety, food tolerance, and weight regain. *Surg Endosc* **36**, 9146–9155 (2022). <https://doi.org/10.1007/s00464-022-09395-4>
3. Lemmens, L., Van Den Bossche, J., Zaveri, H. *et al.* Banded Sleeve Gastrectomy: Better Long-Term Results? A Long-Term Cohort Study Until 5 Years Follow-Up in Obese and Superobese Patients. *OBES SURG* **28**, 2687–2695 (2018). <https://doi.org/10.1007/s11695-018-3248-2>

Ring-augmented RYGB



XXVIII IFSO
World Congress

9-12 September 2025
Santiago, Chile



2x SR:

All RCTs in RYGB demonstrated a 5.6% higher Excess Weight Loss (EWL) than procedures performed without a ring



Meta-analysis encompassing over 8,000 patients who underwent ring-augmented Roux-en-Y gastric bypass with a decade-long follow-up revealed remarkably low complication rates (2.3% for erosion and 1.5% for slippage).

Revisional Procedures

- Recent studies confirm that ring-augmented revisions significantly improve weight loss outcomes, helping patients achieve and maintain better results than non-augmented methods:

Ra Resleeve

Ra RYGB

Boerboom, A., Aarts, E., Lange, V. et al. Banding the Pouch with a Non-adjustable Ring as Revisional Procedure in Patients with Insufficient Results After Roux-en-Y Gastric Bypass: Short-term Outcomes of a Multicenter Cohort Study. *OBES SURG* 30, 797–803 (2020). <https://doi.org/10.1007/s11695-019-04361-x>

van Helmond, S., Jense, M., Verkoulen, G. et al. Pouch Revision in Combination with Placement of a MiniMizer Ring as a Revisional Procedure in Patient with Suboptimal Clinical Response or Recurrent Weight Gain After RYGB. *OBES SURG* 35, 2990–2997 (2025). <https://doi.org/10.1007/s11695-025-07984-5>

Hany, M., Ibrahim, M., Zidan, A. et al. Two-Year Results of the Banded Versus Non-banded Re-sleeve Gastrectomy as a Secondary Weight Loss Procedure After the Failure of Primary Sleeve Gastrectomy: a Randomized Controlled Trial. *OBES SURG* 33, 2049–2063 (2023). <https://doi.org/10.1007/s11695-023-06598-z>



XXVIII IFSO
World Congress

9-12 September 2025
Santiago, Chile

Objectives

- Present case-based examples of ring-related complications.
- Highlight technical considerations for safe ring placement.



XXVIII IFSO
World Congress

9-12 September 2025
Santiago, Chile

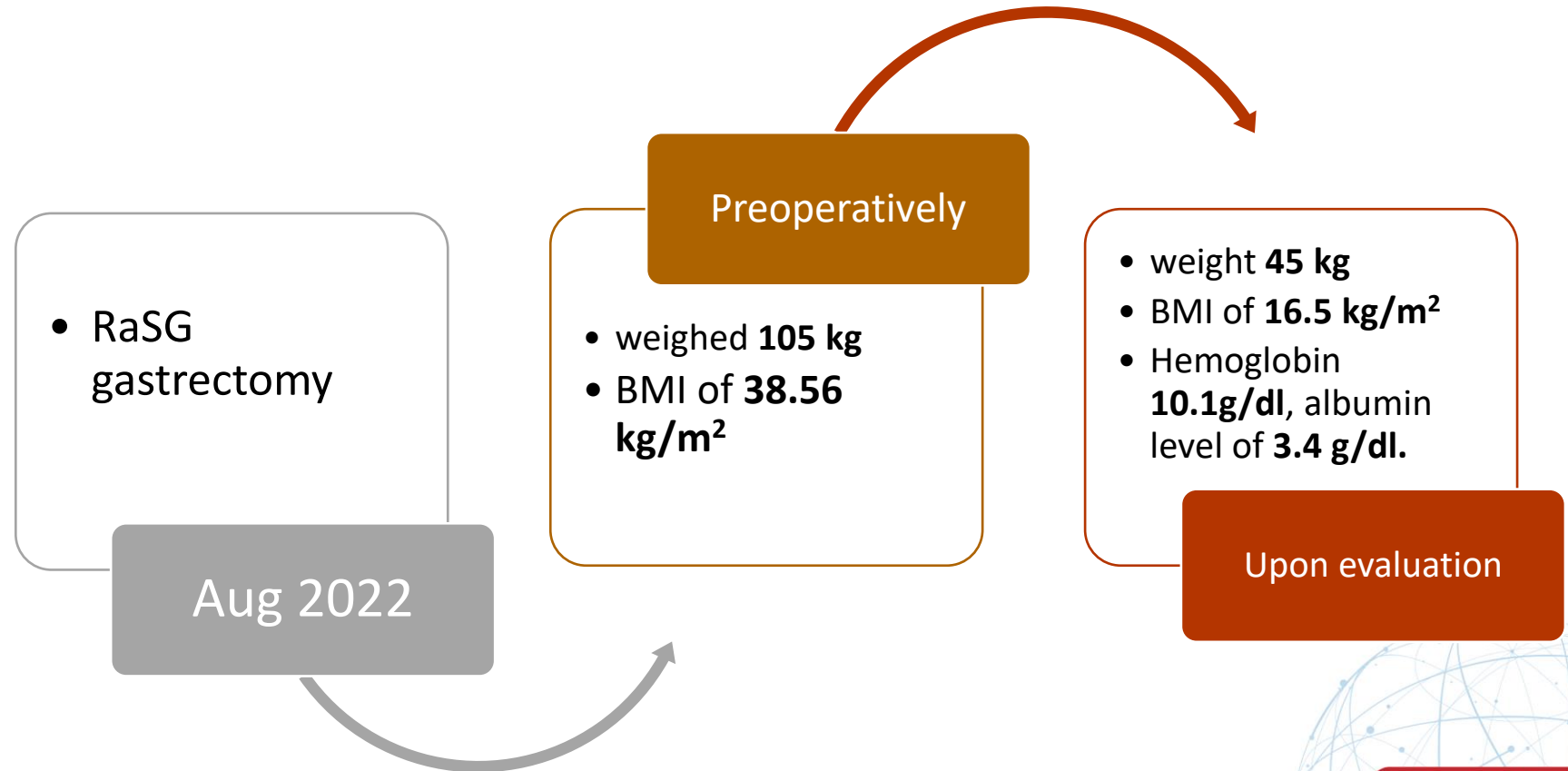

Case 1



XXVIII IFSO
World Congress

9-12 September 2025
Santiago, Chile

- A 23-year-old female presented at the center with a three-month history of persistent vomiting.





XXVIII IFSO World Congress

9-12 September 2025
Santiago, Chile

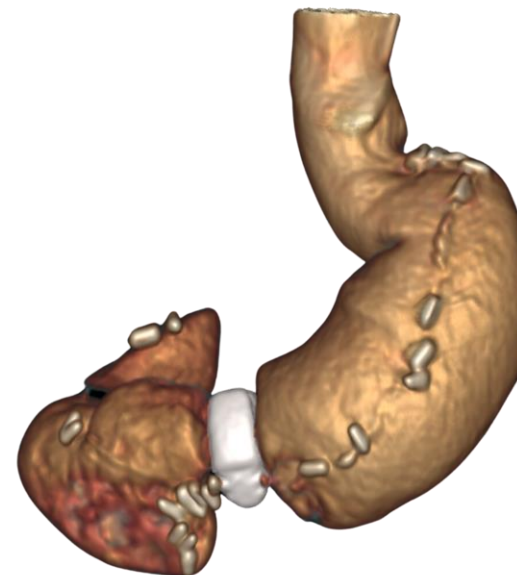Investigations

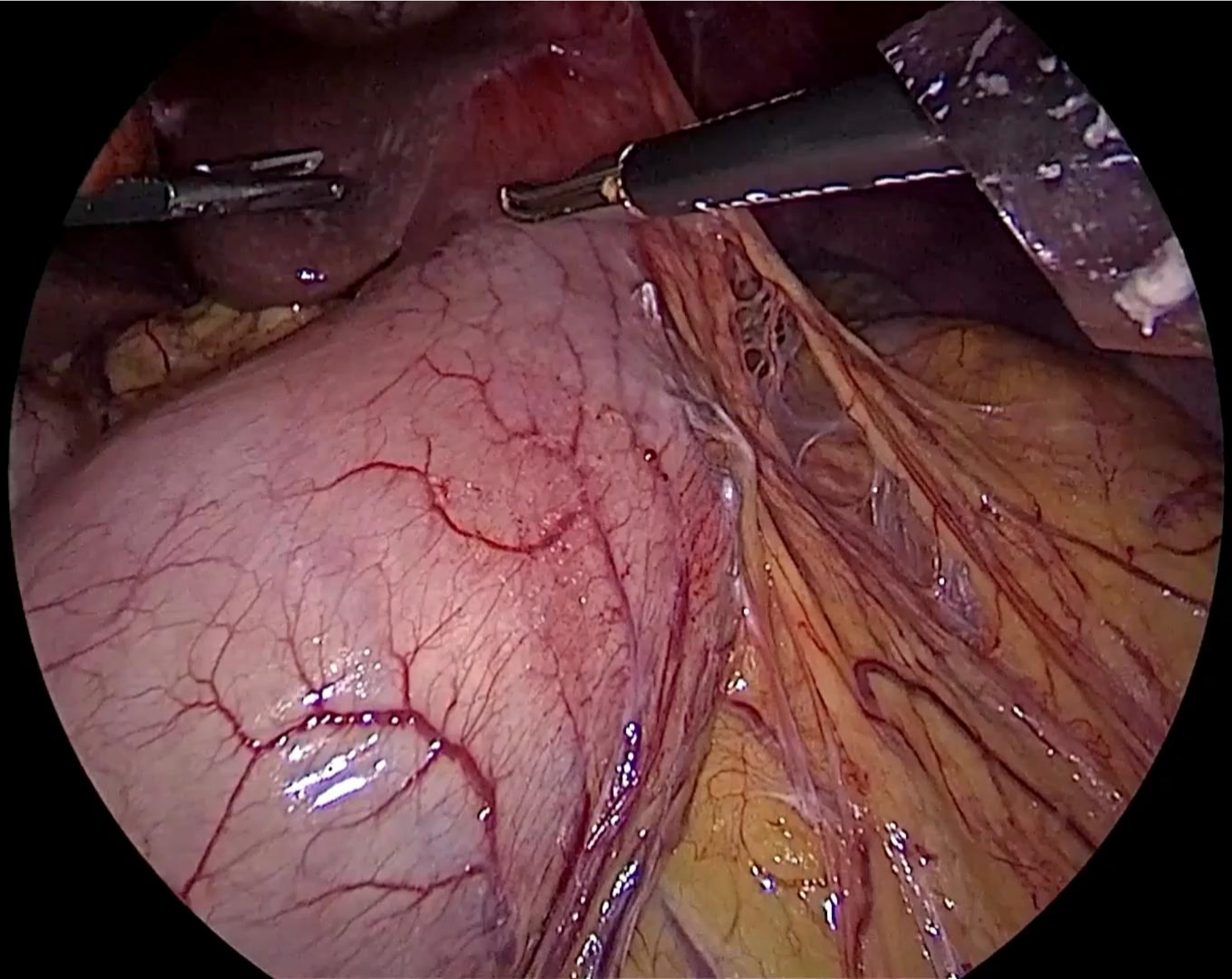
CT with 3D reconstruction:

Gastric pouch dilatation above the band

Complete ring erosion and slippage

Endoscopic passage blocked by the eroded band







**XXVIII IFSO
World Congress**

**9-12 September 2025
Santiago, Chile**

Immediate Postoperative Course

Early tolerance to fluids (Day 1)

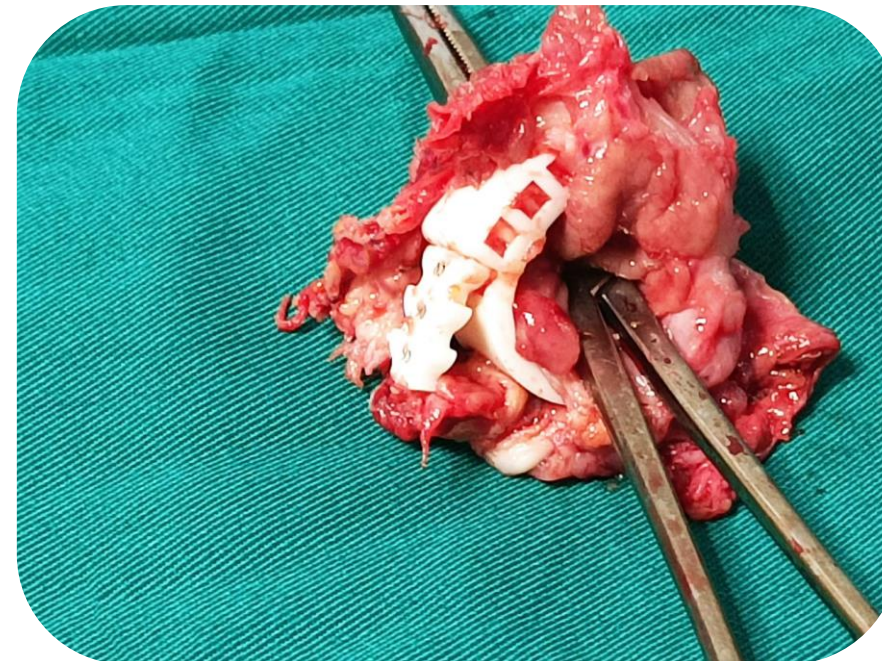
No complications

Discharged by Day 2

Follow-up (2 months)

No recurrent vomiting

Returned to normal diet



Case 2



XXVIII IFSO
World Congress

9-12 September 2025
Santiago, Chile

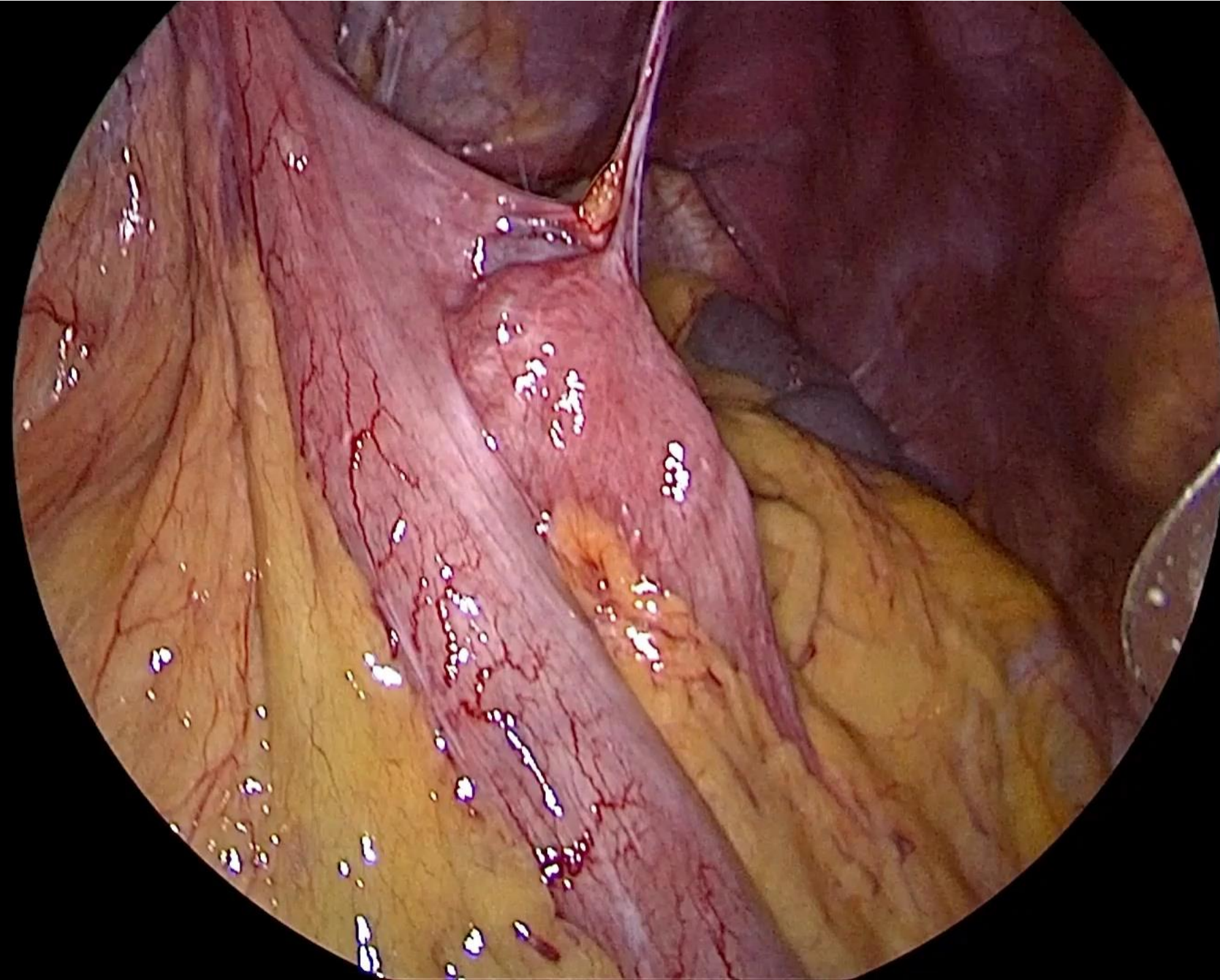
Patient Profile: A 42-year-old female who previously underwent a ring-augmented Roux-en-Y gastric bypass

Initial Course: Two months postoperatively, the patient was doing well.

Complication: Developed progressive dysphagia that did not respond to conservative treatments.

Diagnostic Findings: Upper GI endoscopy revealed a stenosis at the ring site, preventing passage of the endoscope.

Decision: Due to the inability to dilate the stenosis, the plan was made to remove the ring to restore normal passage.





XXVIII IFSO
World Congress

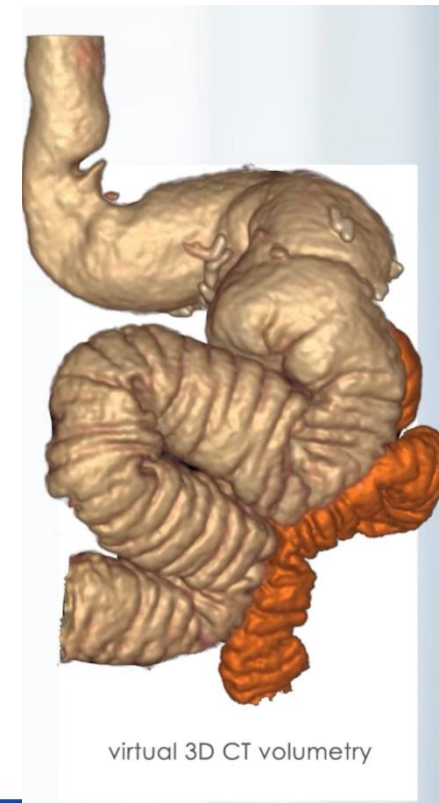9-12 September 2025
Santiago, Chile

Case 3

A 37-year-old female, initial **LSG** in **2014** (BMI 44.8, 122 kg → 71 kg).

Significant **RWG** by **2018** (103 kg) + symptomatic **GERD** → underwent **RYGB** at another center.

Suboptimal results: only 12 kg lost, a persistent large pouch (200 cc) + long blind “candy cane” limb on imaging.



ifso2025.org

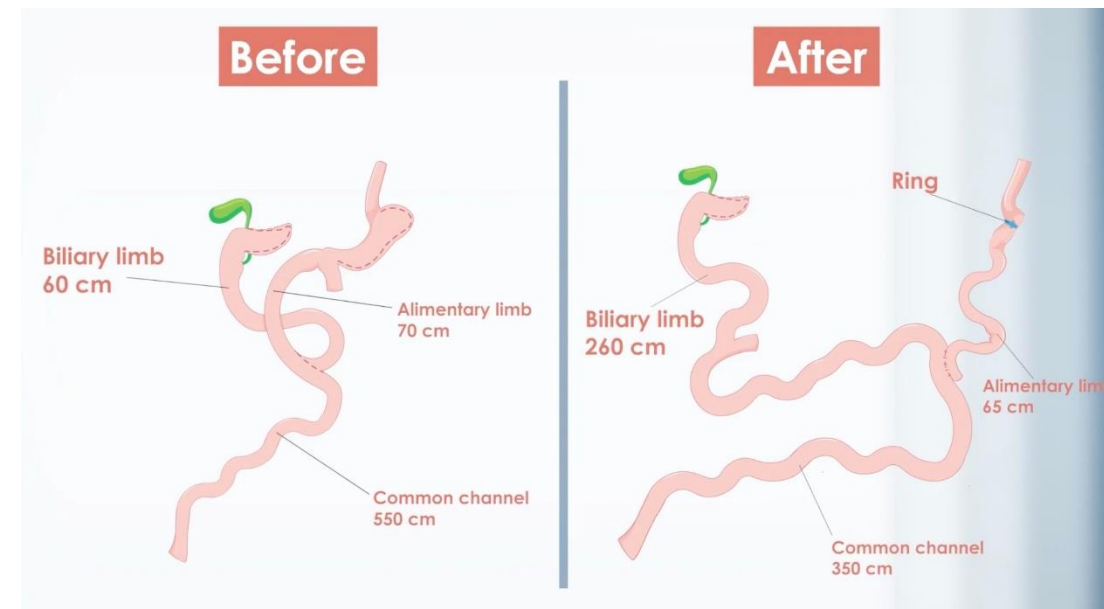
Revision

Pouch and stoma resized over 40 Fr bougie

Limb lengths adjusted: AL 70 cm, BL 260 cm, CC 350 cm

Minimizer silicone ring placed loosely around the pouch

Discharged POD2





XXVIII IFSO
World Congress

9-12 September 2025
Santiago, Chile

Early Outcome

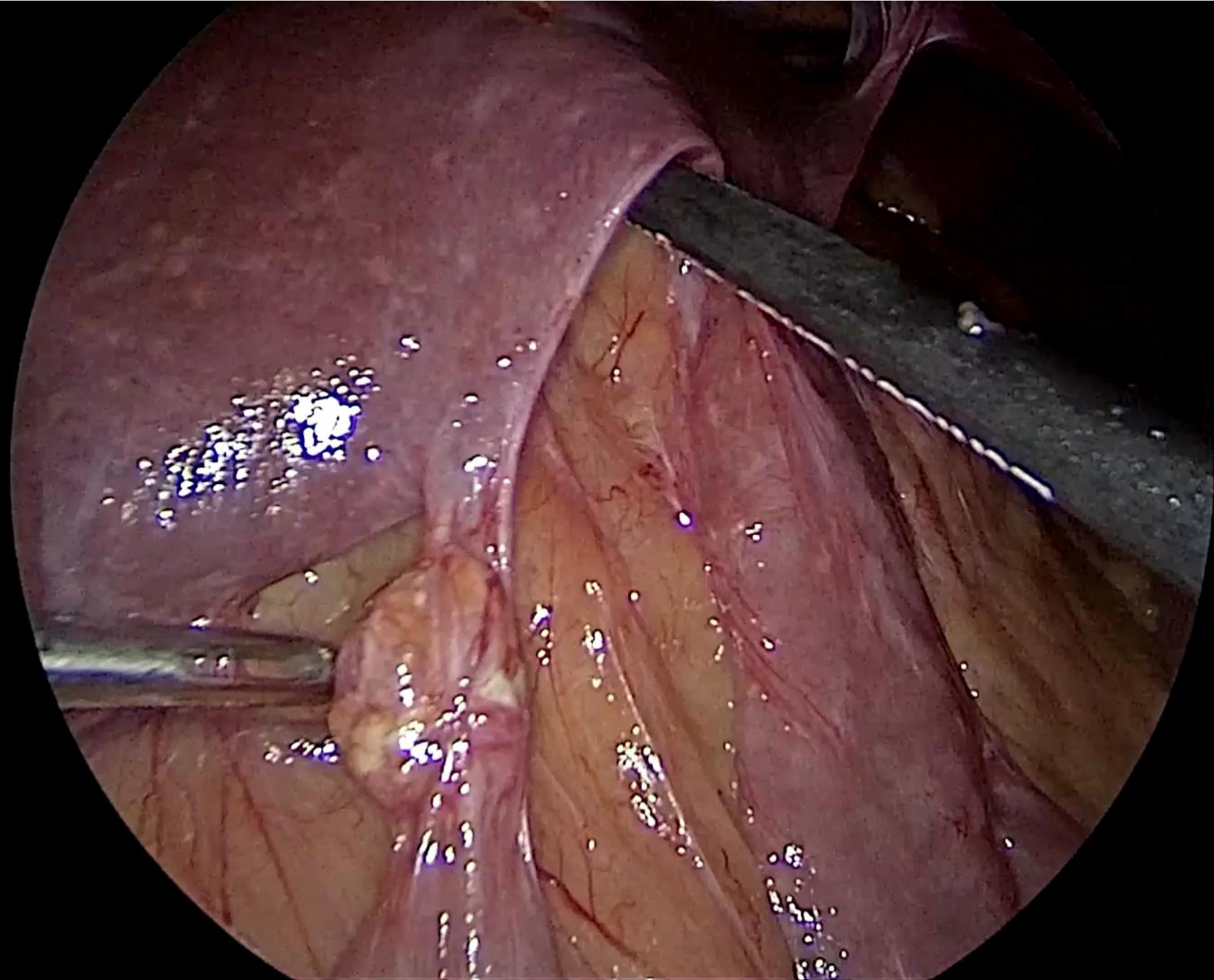
Initial 12 kg weight loss within 2 months

Complications

Progressive dysphagia, reduced food tolerance, persistent symptoms despite PPIs

Endoscopy: **partial ring erosion with gastric ulceration (3 months after surgery)**

Failed endoscopic removal → required surgical removal.





XXVIII IFSO World Congress

9-12 September 2025
Santiago, Chile

Final Result

Uneventful recovery, symptoms resolved

By Sept 2024: total weight loss 27 kg → BMI 27.9 kg/m²



Technical Considerations

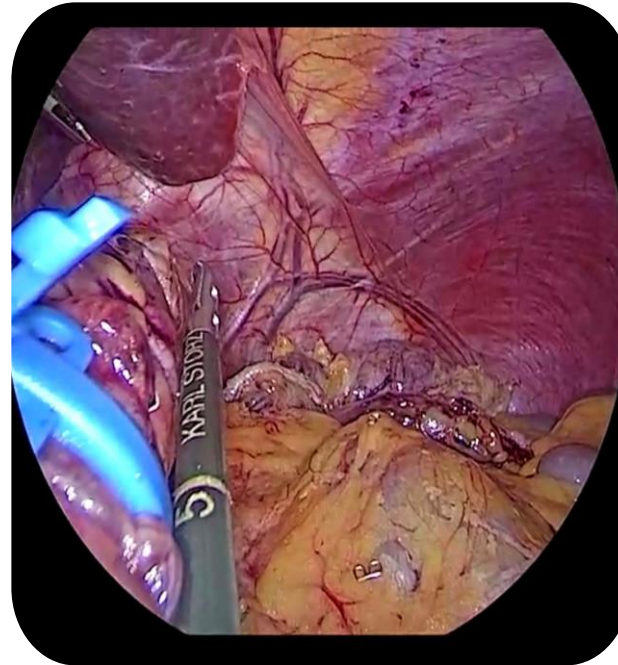


XXVIII IFSO
World Congress

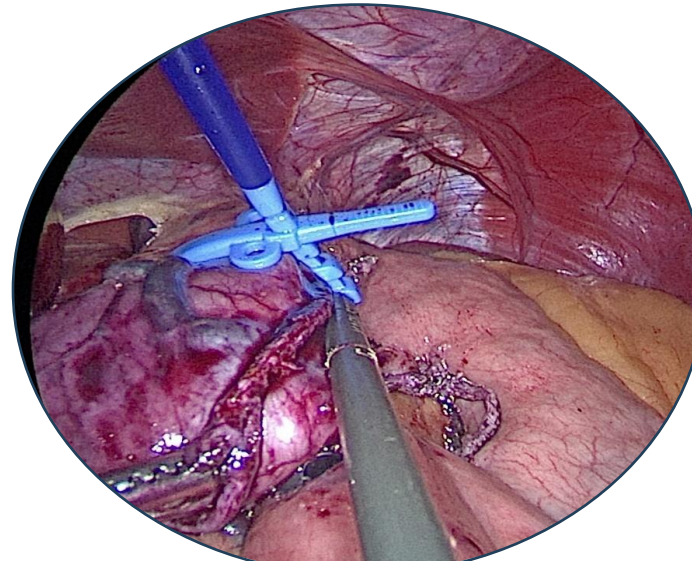
9-12 September 2025
Santiago, Chile

Positioning

Sleeve: 3–5 cm below gastroesophageal junction.

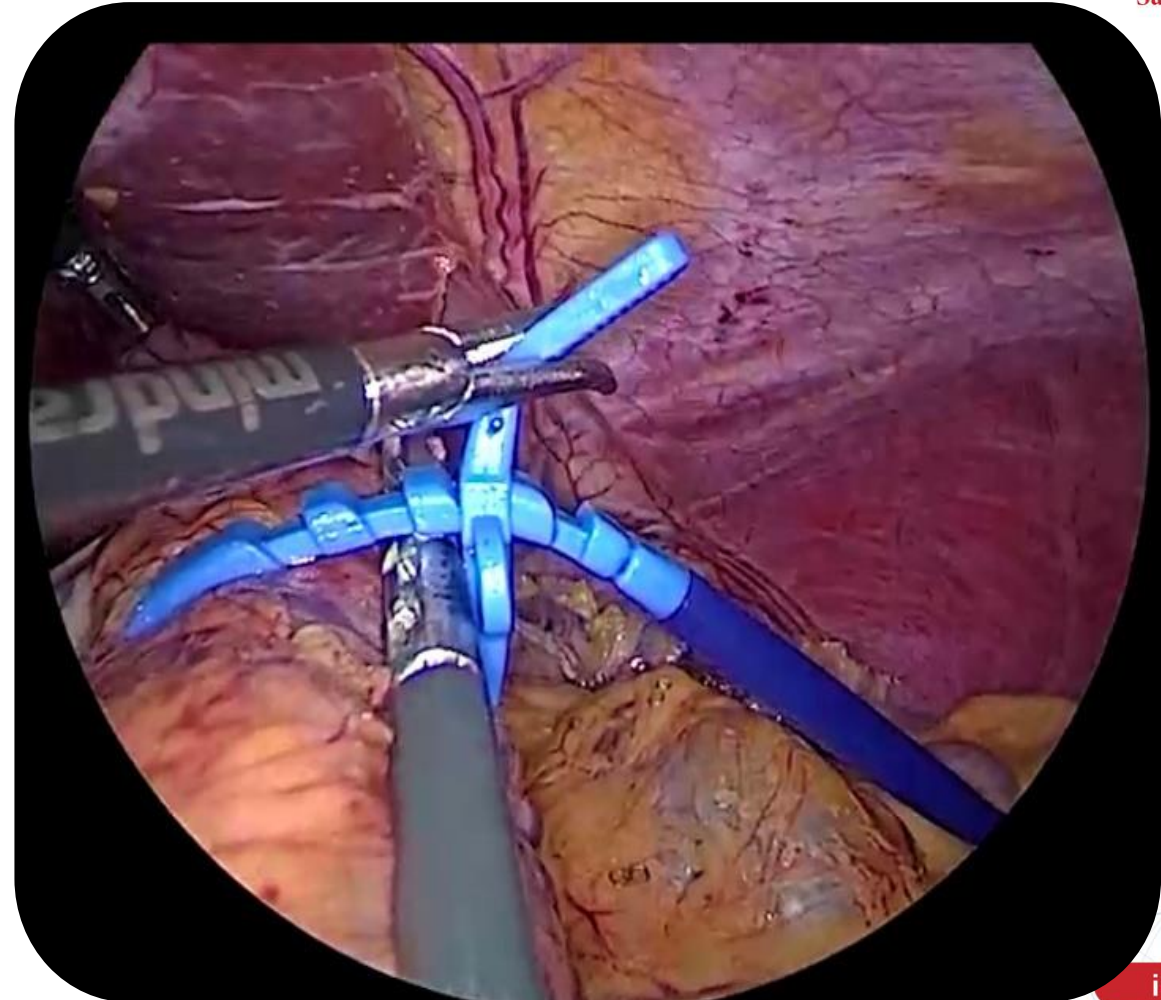


Bypass: ~3 cm above gastro-jejunosotomy.



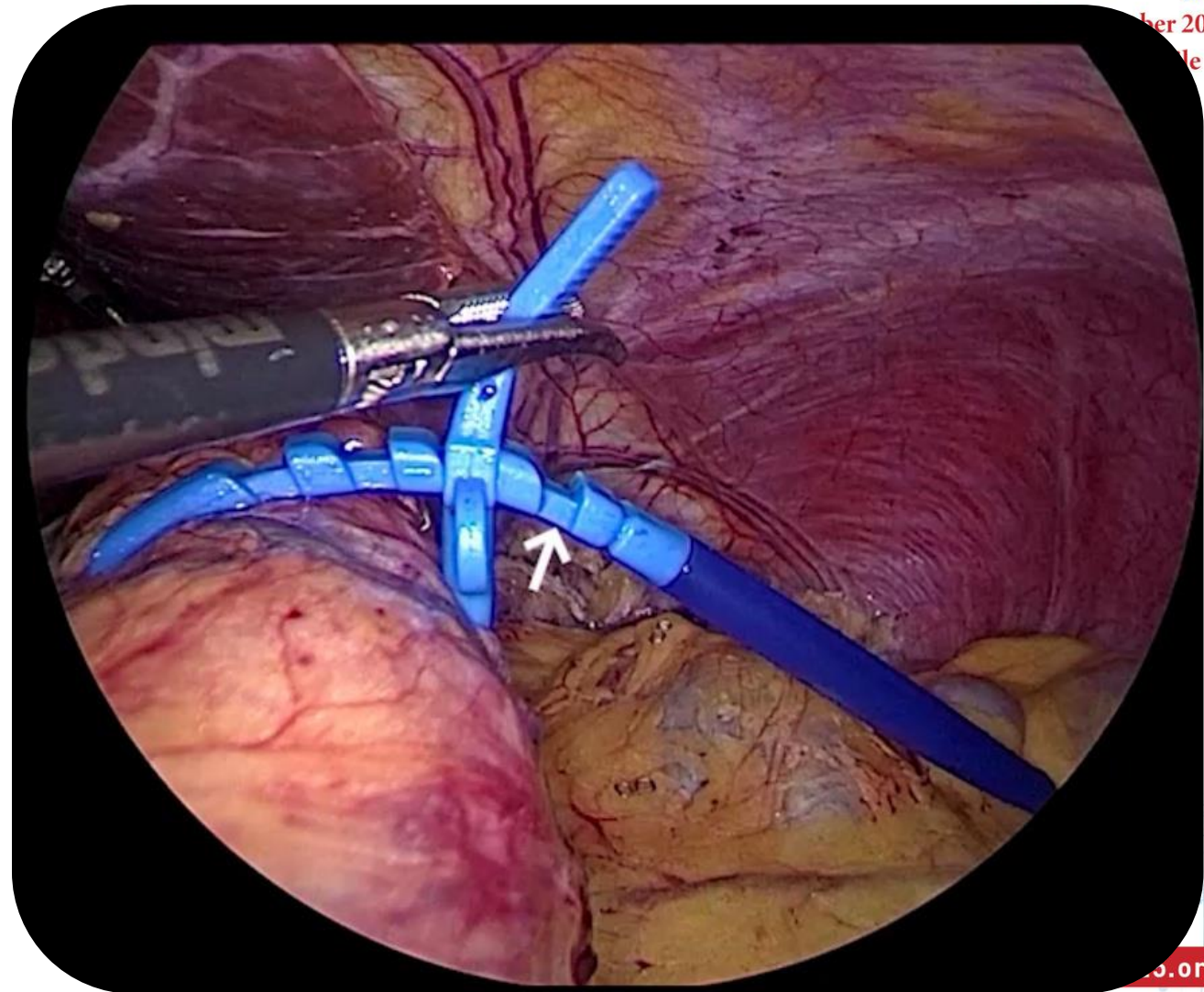
Tension

- **Avoid Excess Tightness:** Ring must be loose enough to prevent dysphagia, regurgitation, or ischemia.
- **Instrument Passage Check:** Ensure a 5 mm instrument can pass easily between the pouch and the ring, confirming adequate looseness



Tension

- **Avoid Excess Tightness:** Ring must be loose enough to prevent dysphagia, regurgitation, or ischemia.
- **Instrument Passage Check:** Ensure a 5 mm instrument can pass easily between the pouch and the ring, confirming adequate looseness



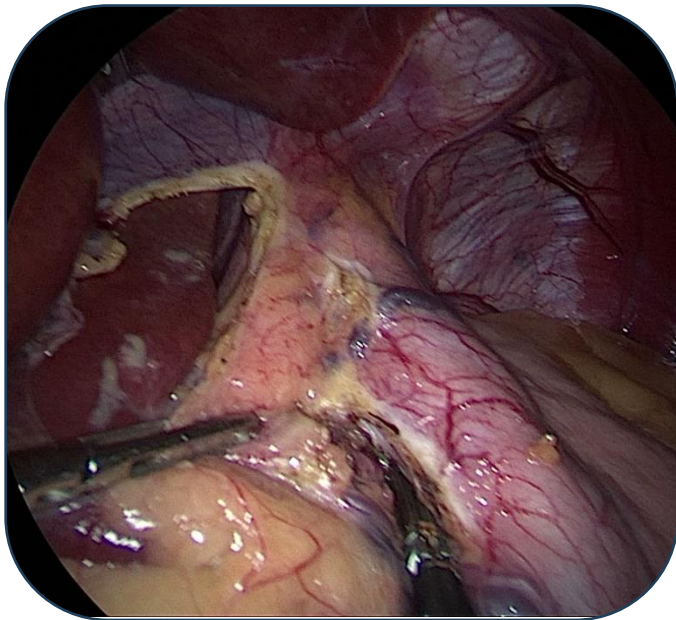


XXVIII IFSO
World Congress

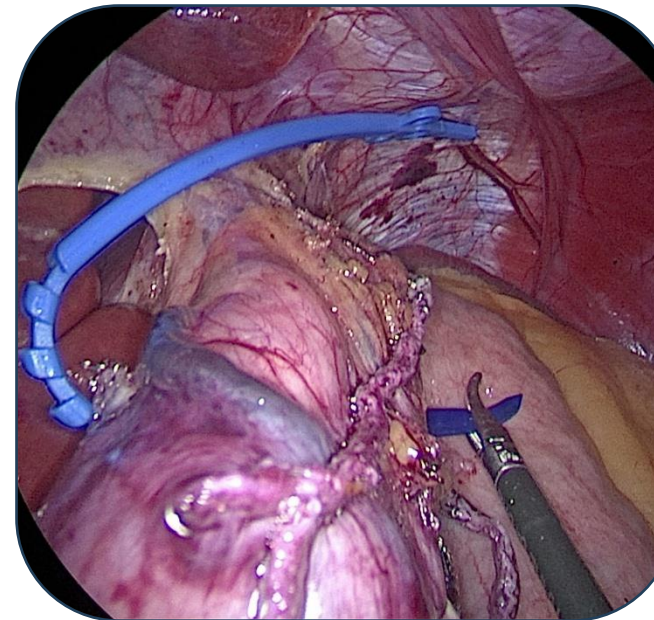
9-12 September 2025
Santiago, Chile

In RYGB

Dissect the lesser sac below the
third vein for the construction
of a long pouch RYGB
(Expanded pouch)



Passage of the ring
(Perigastric technique)

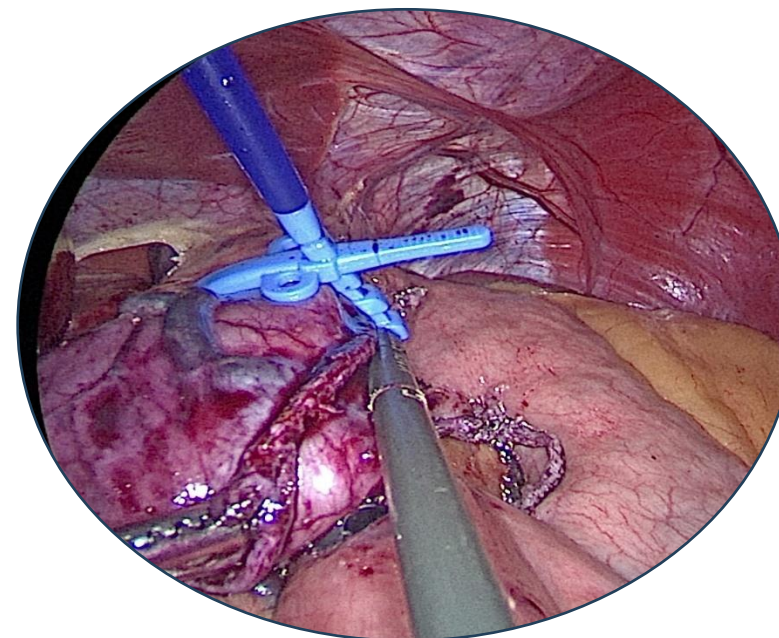
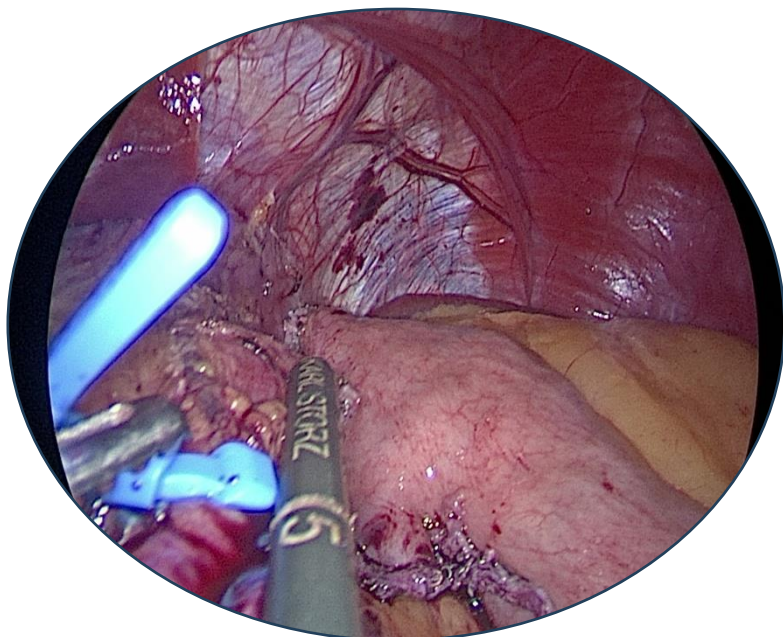


Pouch Length (RYGB)

Maintain pouch length 8–10 cm above the gastro-
jejunostomy

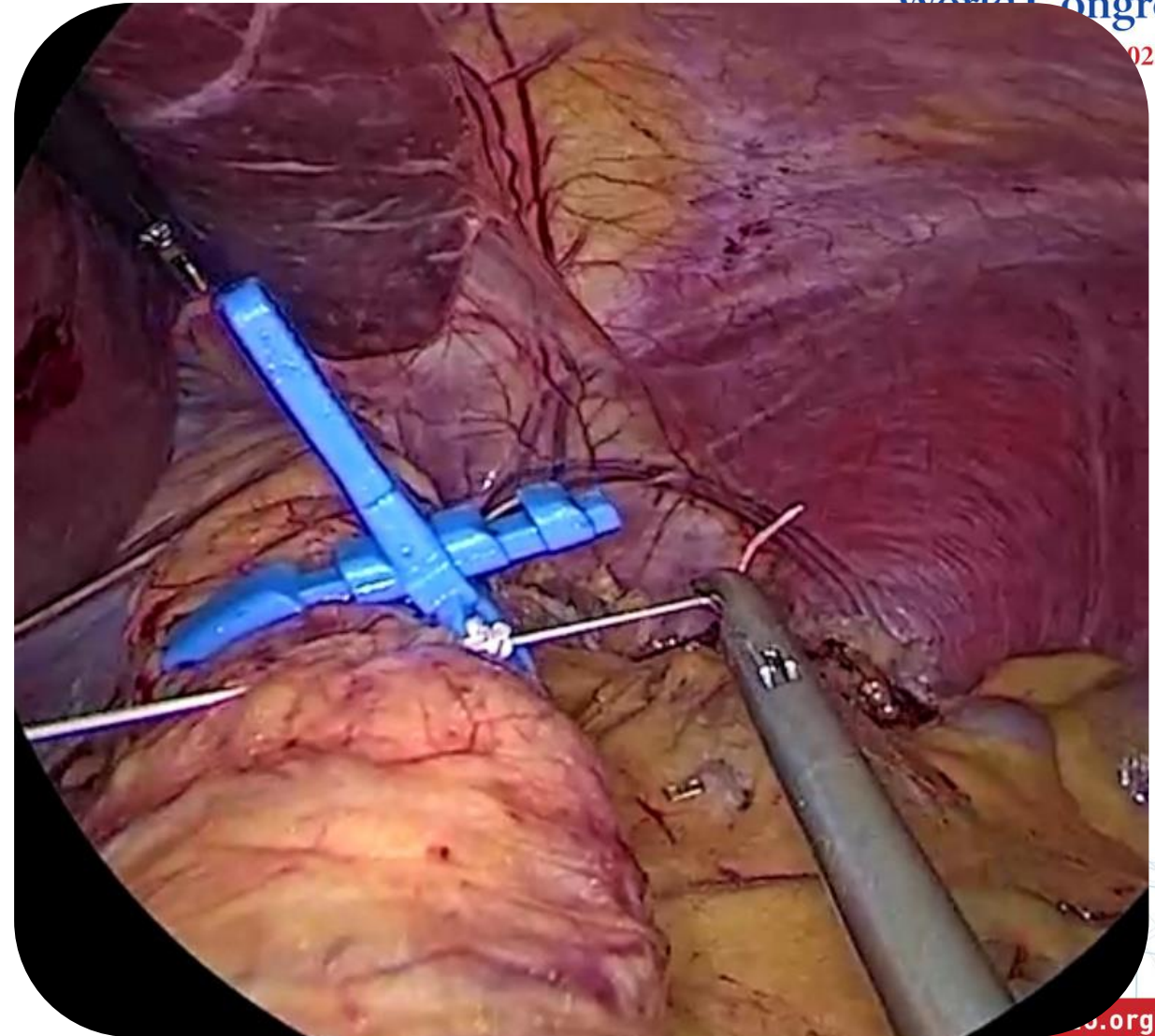
Followed by application and tightening

Prevents migration of the alimentary
limb between the pouch and the ring



Ring Fixation

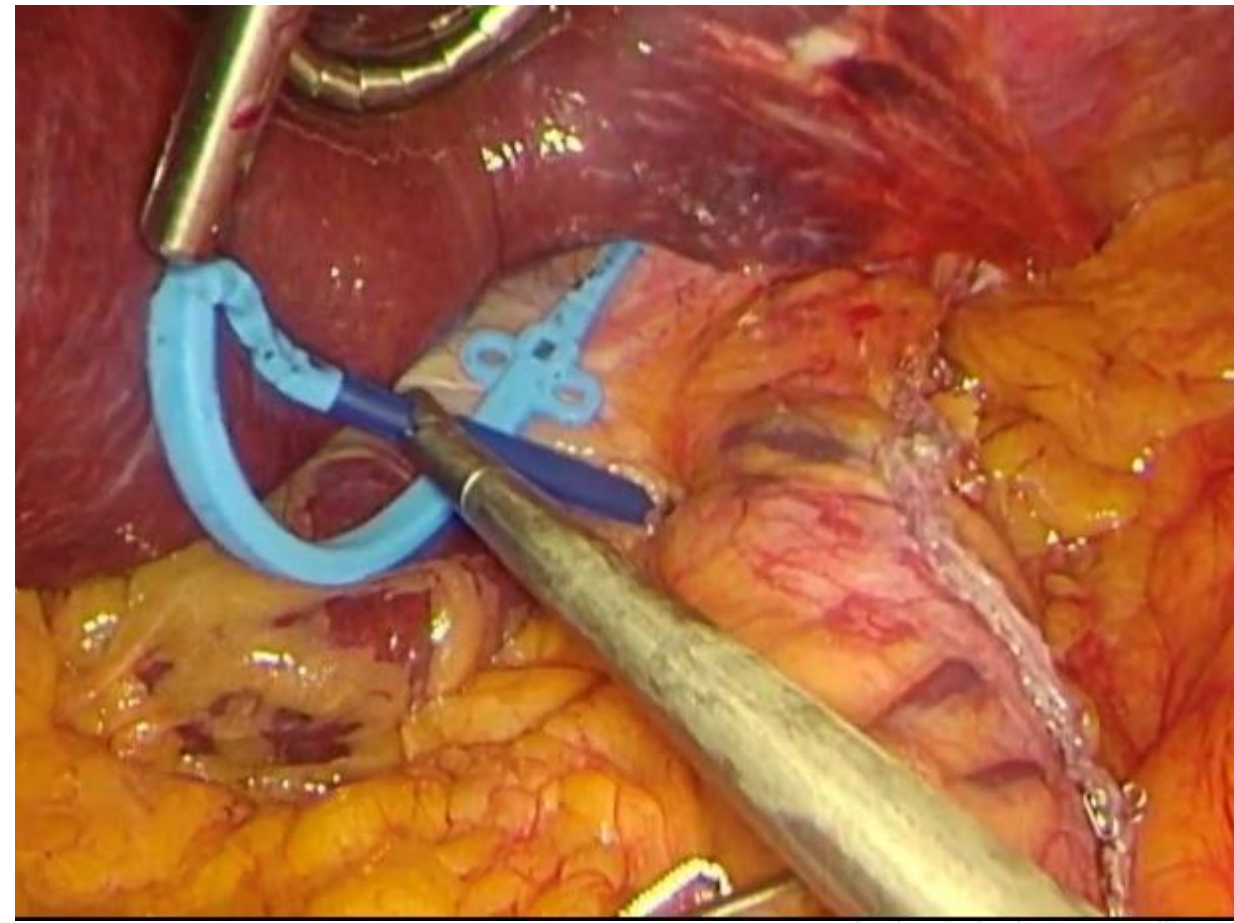
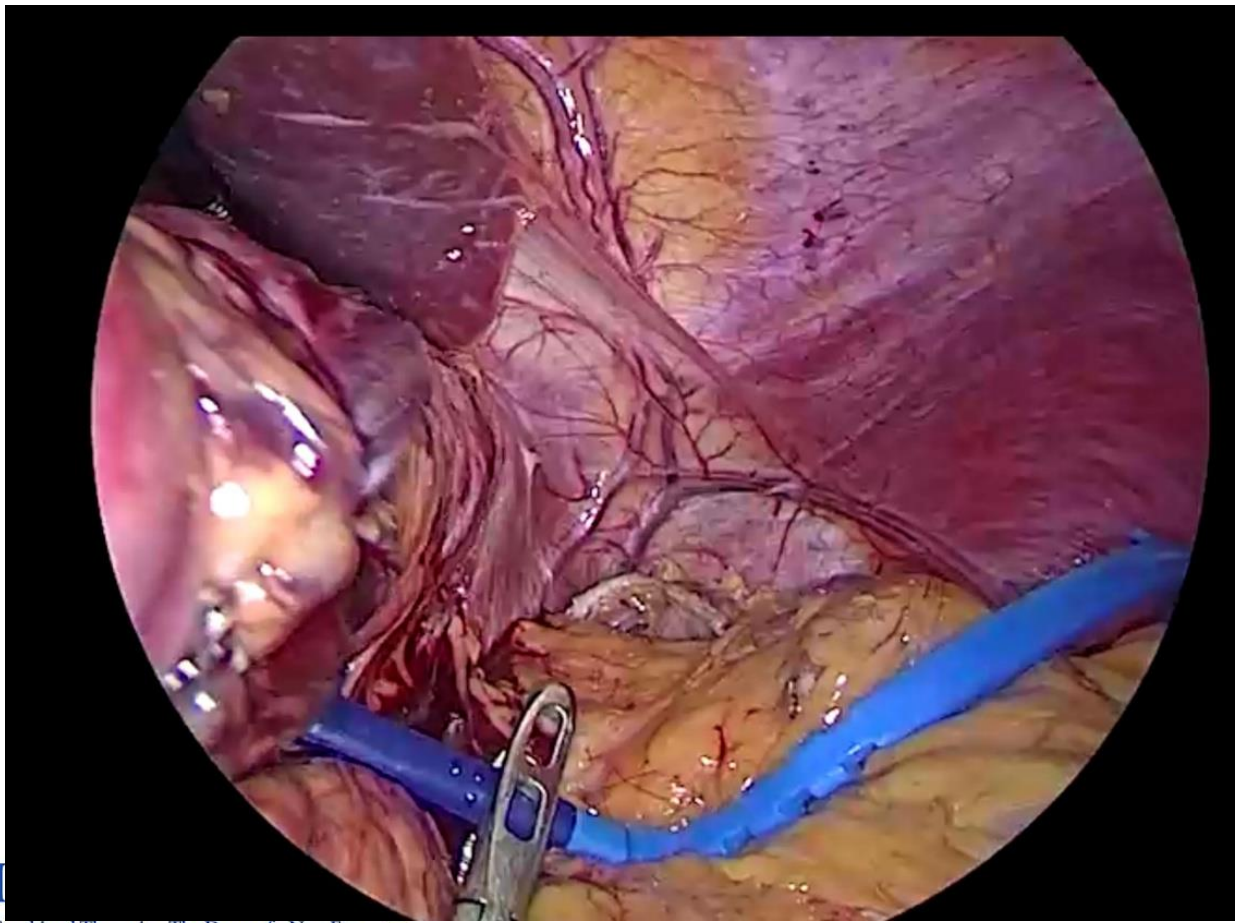
- Use **non-absorbable sutures** through the built-in ring holes to prevent long-term slippage.
- **Avoid Fat Layer:** Ensure direct contact between the ring and the gastric wall; remove perigastric fat.



Techniques of Placement

Perigastric tunnel –
created close to
gastric wall

Pars flaccida approach – through
the gastro-hepatic ligament.



Takeaway Messages



XXVIII IFSO
World Congress

9-12 September 2025
Santiago, Chile

1. **Efficacy vs. Risk:** Ring-augmented MBS enhances long-term weight loss but carries unique risks, with ring erosion being rare yet serious.
2. **Early Detection:** follow-up and immediate endoscopic evaluation of symptoms such as dysphagia or intolerance are critical for timely diagnosis.
3. **Safe Management:** Optimal outcomes depend on meticulous surgical technique and minimally invasive management by experienced teams to relieve symptoms, prevent complications, and preserve bariatric efficacy.





XXVIII IFSO World Congress

9-12 September 2025
Santiago, Chile

Thank you