

Case 1

NAC Team

Richard Peterson MD FACS

Tammy Kindel MD FACS

Rana C Pullatt MD FACS



56 y/o Female Patient

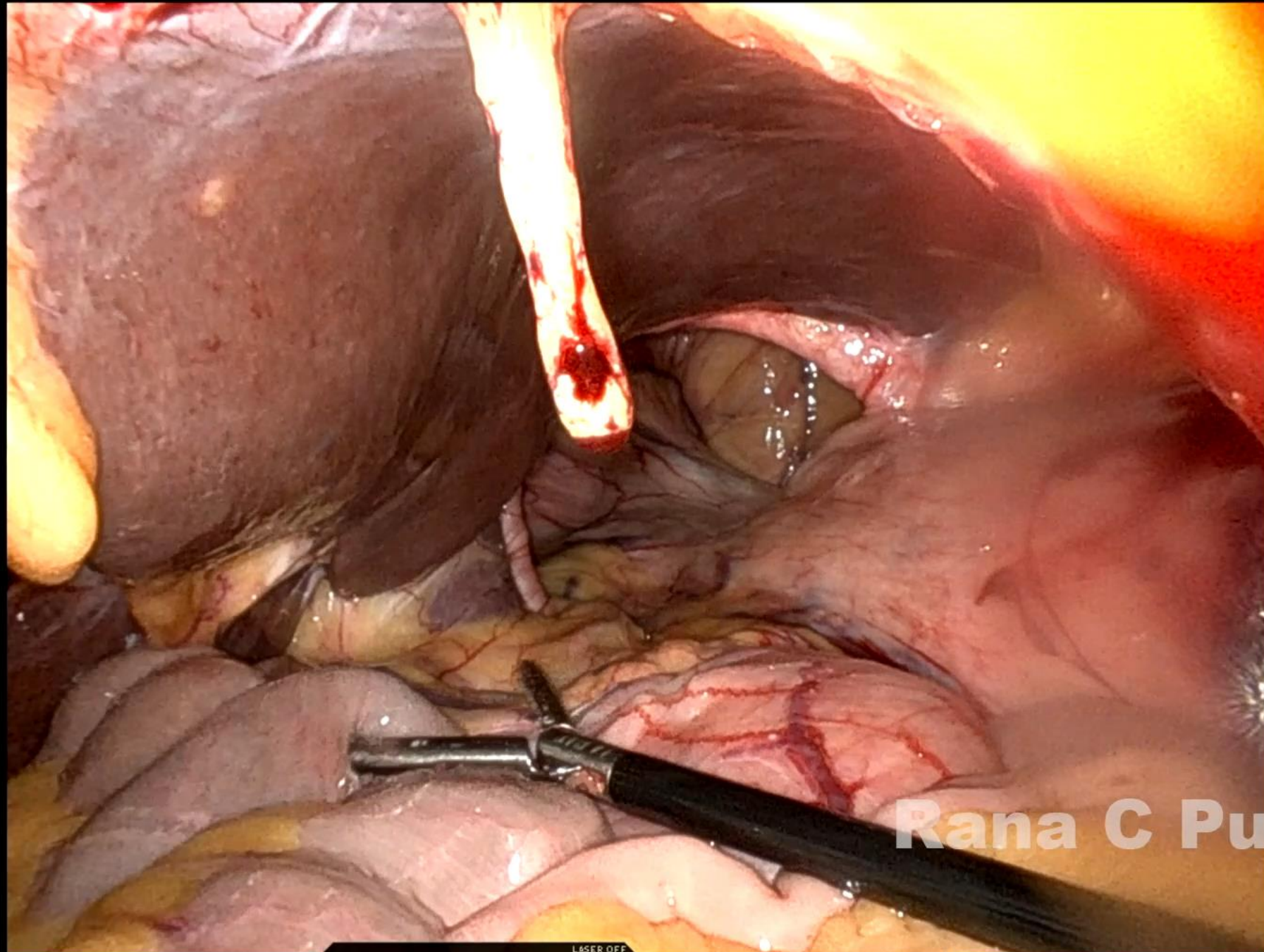
Ef-25%

On eliquis unprovoked PE

GERD, Bmi-41, Hiatal Hernia

OSH Surgeon tried to repair 3 months ago

Jehovah's Witness (will not accept Blood)



Rana C Pullatt

1 2 3 4

LASER OFF

18° REV 0° 1x 30°

This block contains the laparoscopic console's control interface. It features four numbered buttons (1, 2, 3, 4) for camera and instrument control. Between buttons 2 and 3, there are icons for camera rotation (18° REV), a hexagonal icon, and a camera zoom/tilt indicator (0° and 1x 30°). The text 'LASER OFF' is displayed above the zoom indicator.



May 3rd-7th

"NO ONE LEFT BEHIND"

WWW.ASMBSMEETING.COM

ASMBS INVITES **YOU**
TO JOIN US!

ASMBS PRESIDENT
RICHARD PETERSON
MD MPH FACS FASMBS DABS-FPMBS

PROGRAM COMMITTEE CHAIR
ADRIAN DAN
MD MPH FACS FASMBS DABS-FPMBS

PROGRAM COMMITTEE CO-CHAIR
MATTHEW BRENGMAN
MD MHA FASMBS DABS-FPMBS

PROGRAM COMMITTEE CO-CHAIR SELECT
OMAR GHANEM
MD FACS FASMBS



Thank You

pullattr@gmail.com