



# XXVIII IFSO World Congress

9-12 September 2025 | Santiago, Chile

## Emergency Gastric Remnant Complications after Laparoscopic Roux-en-Y Gastric Bypass

*JPh M ma K MAGEMA, M.D.*

*CHU UCL Namur, Dinant  
Belgium*

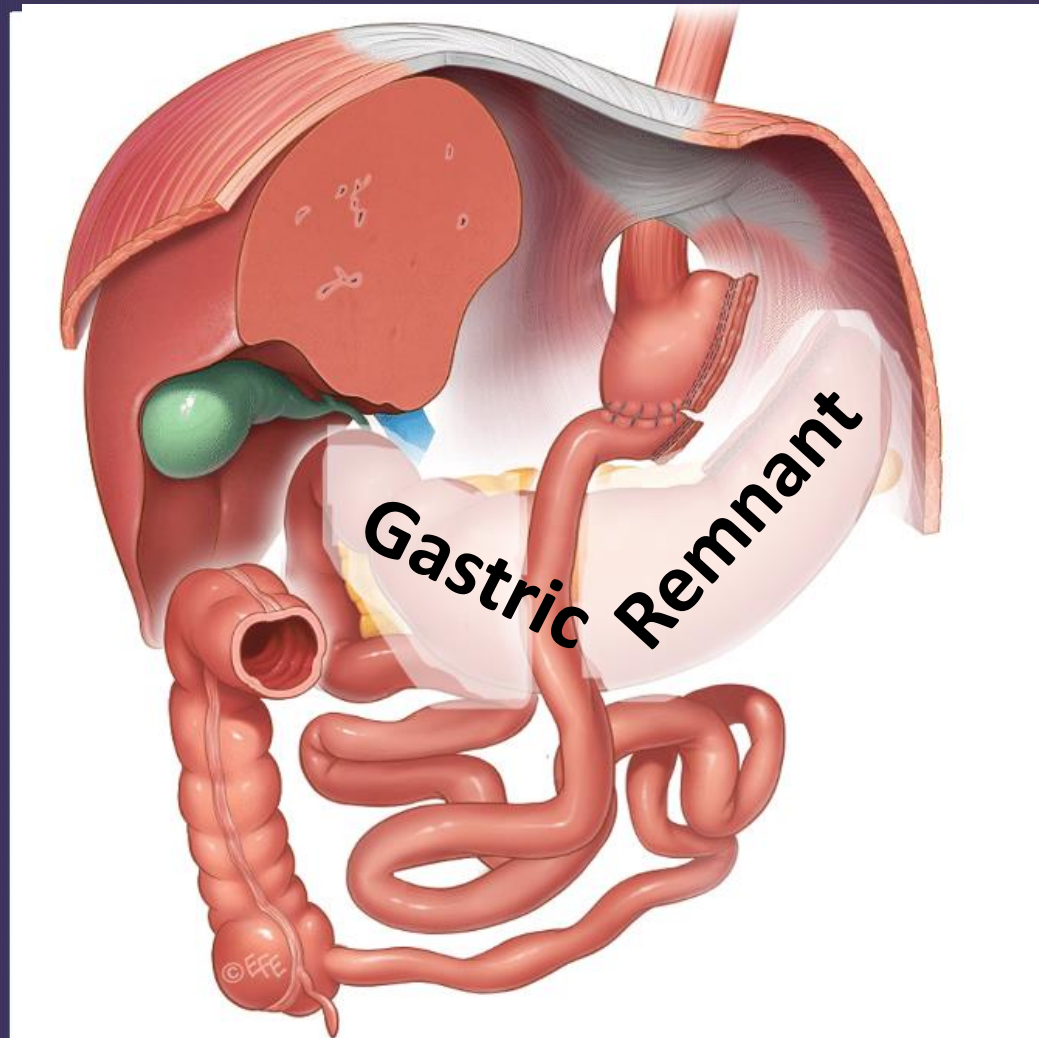*jphmagma@yahoo.fr*

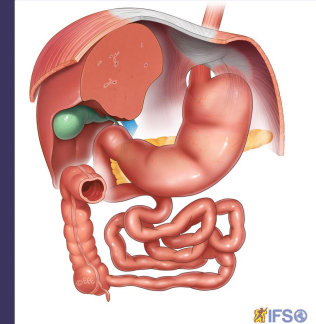
IFSO 2025  
Santiago

Combined Therapies, The Dawn of a New Era

[ifso2025.org](http://ifso2025.org)

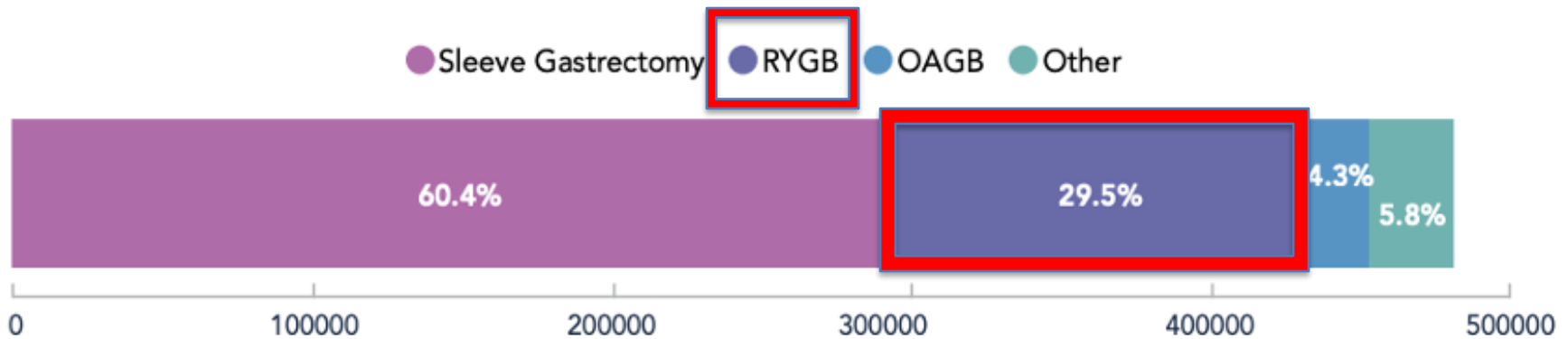
# RYGB - Gastric bypass





Procedures & Operative approach

> 150 K/y

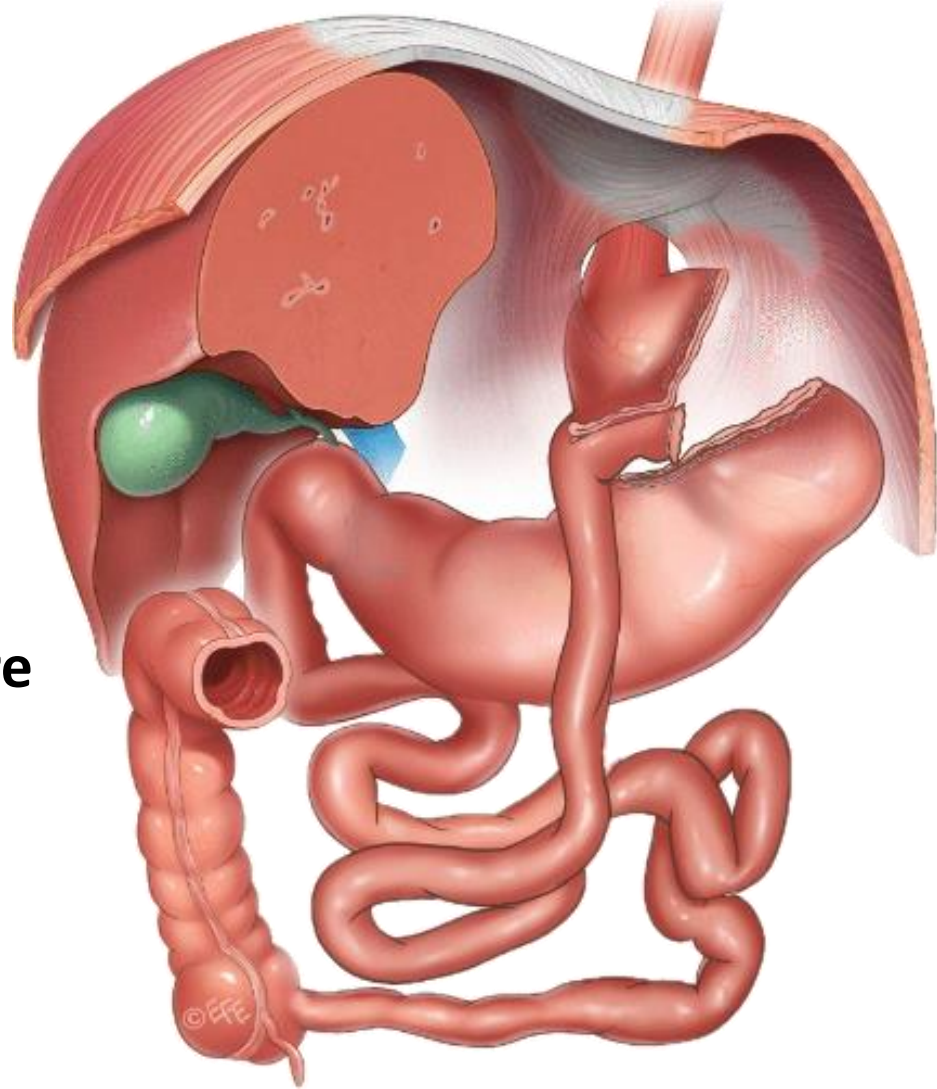
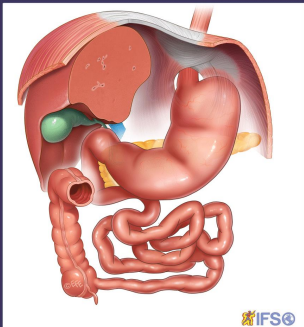


All procedure types (n=480,970).

\*potential for 10,437 procedures to be represented twice due to possible overlaps with the datasets of USA and Michigan.

All procedure types (n=480,970).

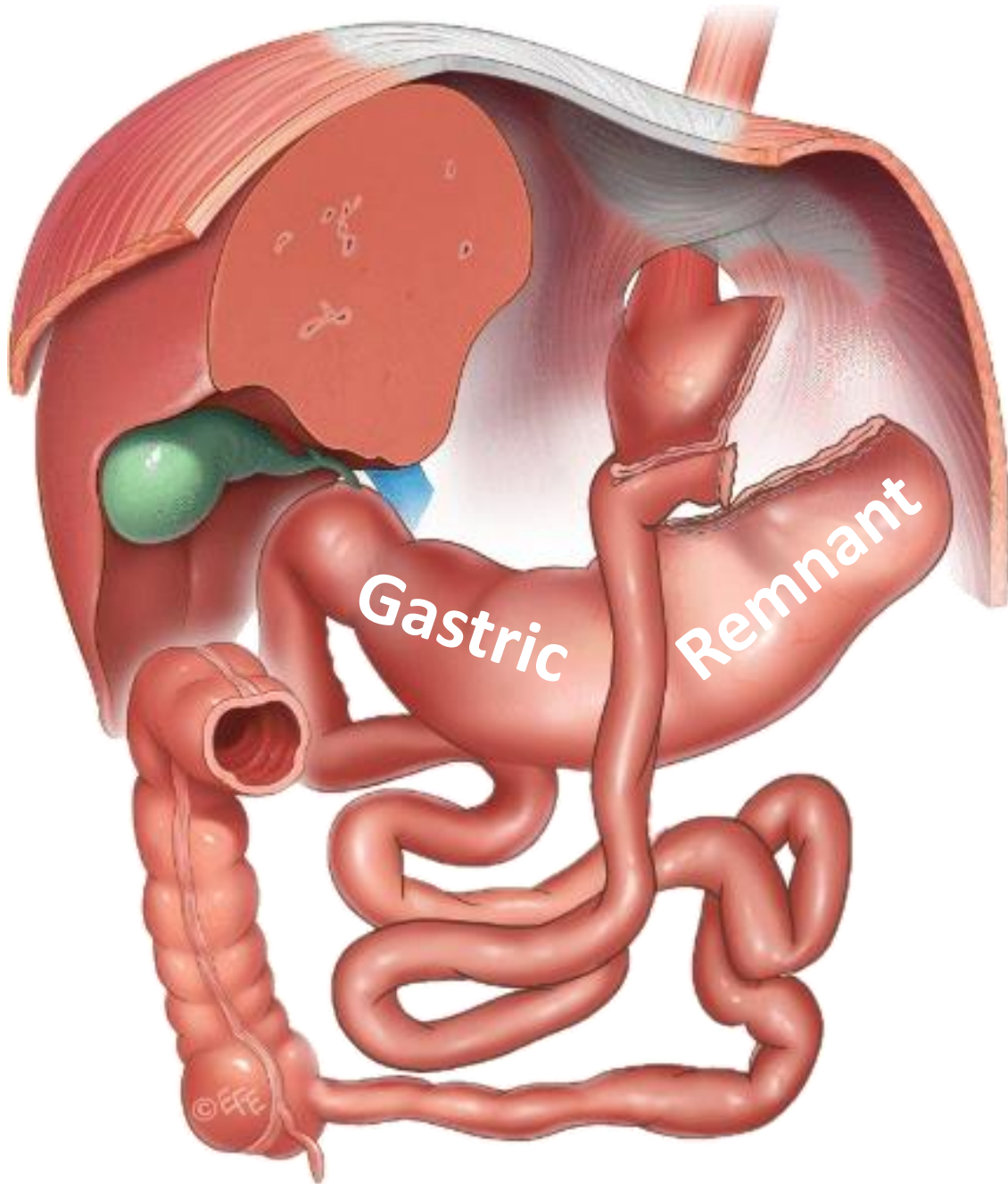
\*potential for 10,437 procedures to be represented twice due to possible overlaps with the datasets of USA and Michigan.



**Widely used an EFFECTIVE procedure**

- ✓ **Management of obesity**
- ✓ **Management of obesity related commorbidities**

**Acceptable complication rate**



**Dead-end pouch**

**Limited  
access to  
DIAGNOSTIC  
and  
THERAPEUTIC  
procedures**





**No Disclosure**

**Emergency** Gastric Remnant Complications after  
Laparoscopic Roux-en-Y Gastric Bypass

*JPh M ma K MAGEMA, M.D.*

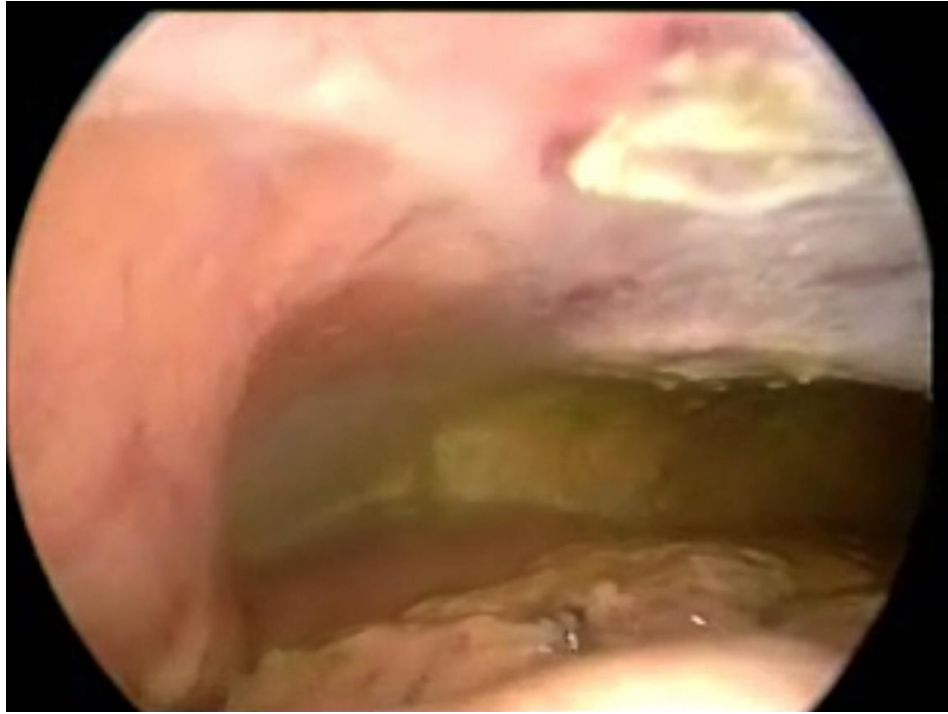*CHU UCL Namur, Dinant  
Belgium*

*jphmagema@yahoo.fr*

**IFSO 2025  
Santiago**

**Combined Therapies, The Dawn of a New Era**

**ifso2025.org**



**PERITONITIS**

**BLEEDING**



A laparoscopic view of the abdominal cavity showing a perforation in the peritoneum. The perforation is a small, dark, circular opening in the peritoneal wall, surrounded by a reddish, inflamed area. The surrounding peritoneum is a pale, yellowish color. The text "Peritonitis: Perforation" is overlaid in white on the image.

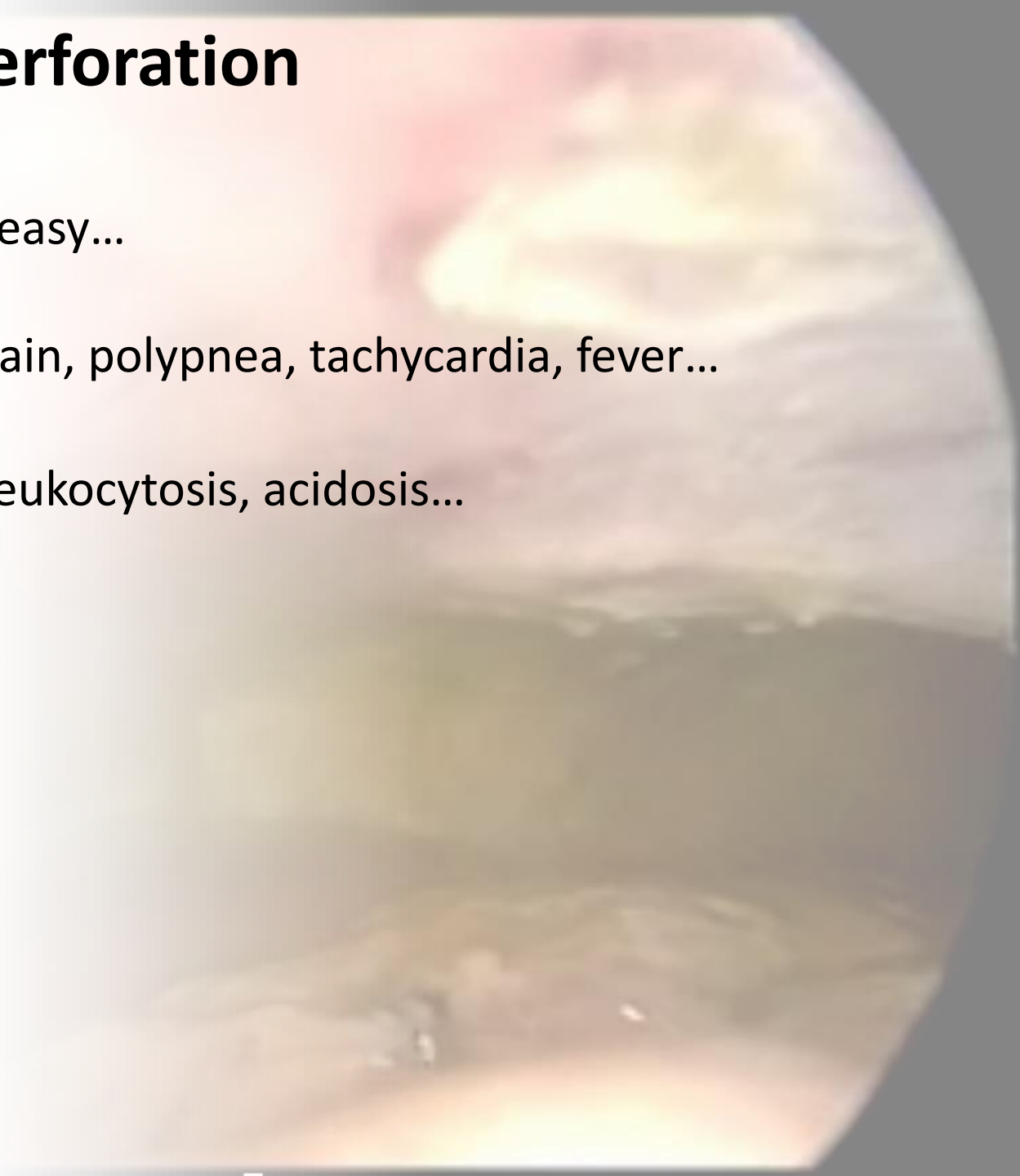
**Peritonitis: Perforation**

# Peritonitis: Perforation

**Clinical:** Quite easy...

Severe abdominal pain, polypnea, tachycardia, fever...

**Blood tests:** Leukocytosis, acidosis...



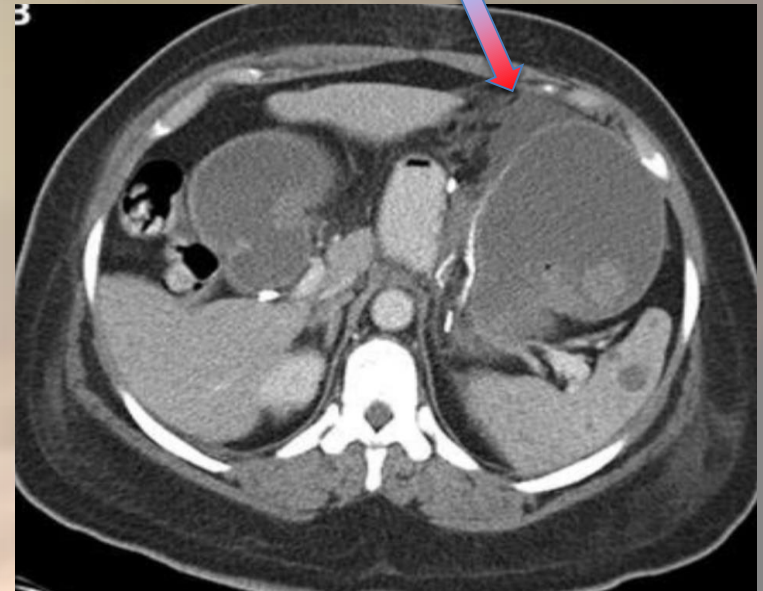
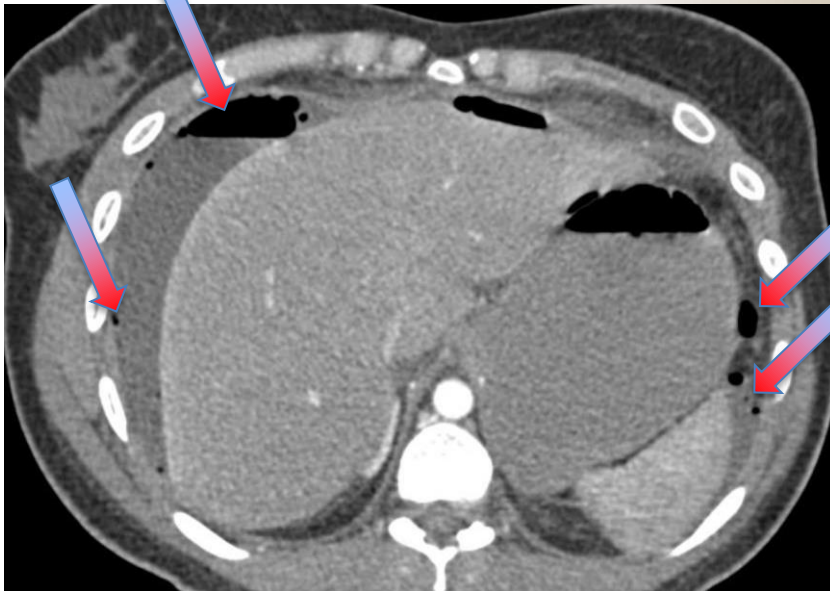
# Peritonitis: Diagnosis

**Clinical:** Quite easy...

Severe abdominal pain, polypnea, tachycardia, fever...

**Blood tests:** Leukocytosis, acidosis...

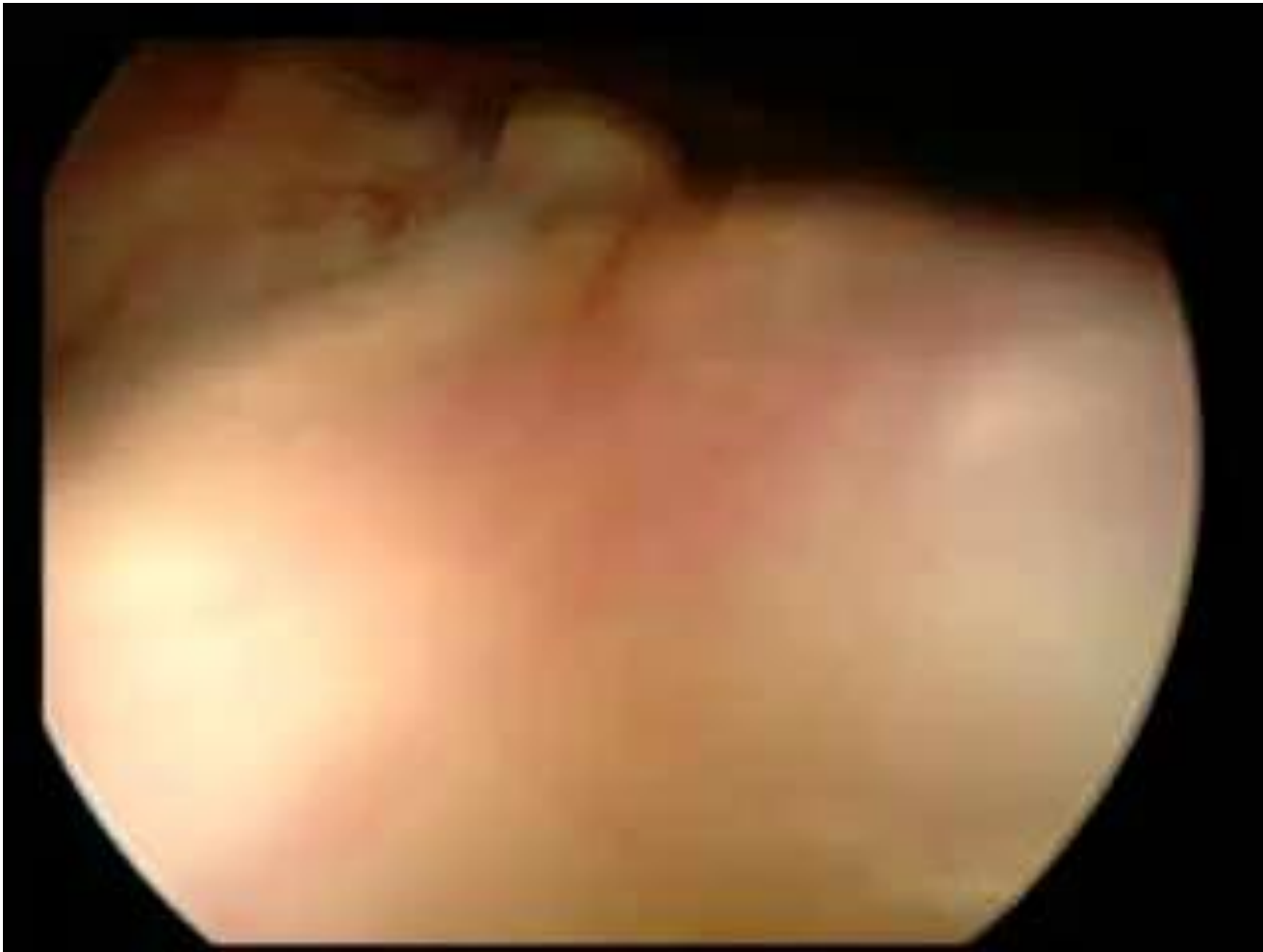**Radiological:** Can be not so evident to see a “classical” hollow organ perforation



# Peritonitis:

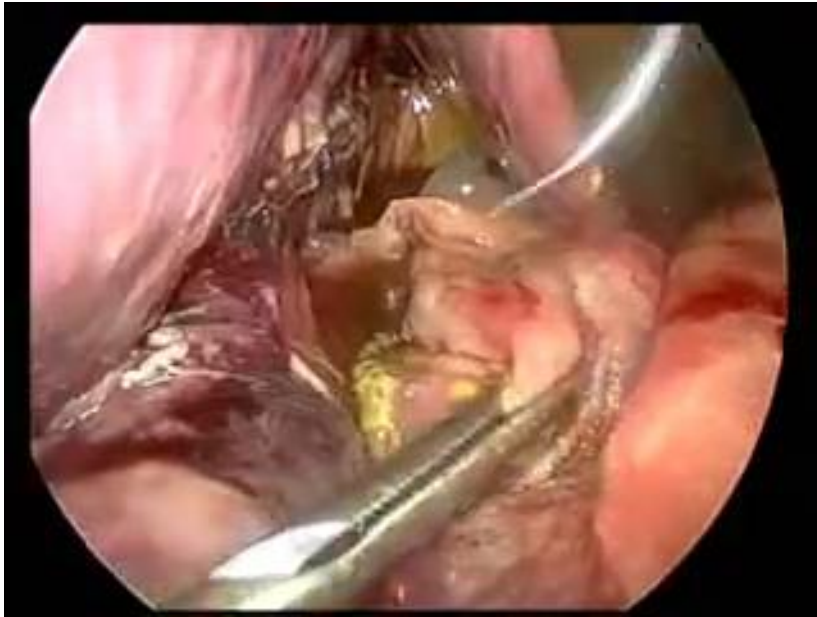
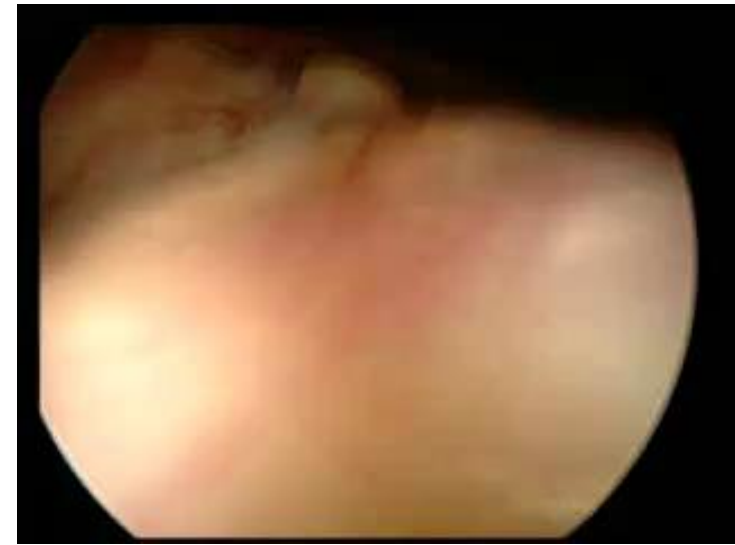**Management: Surgical:**

Laparoscopy? Laparotomy?



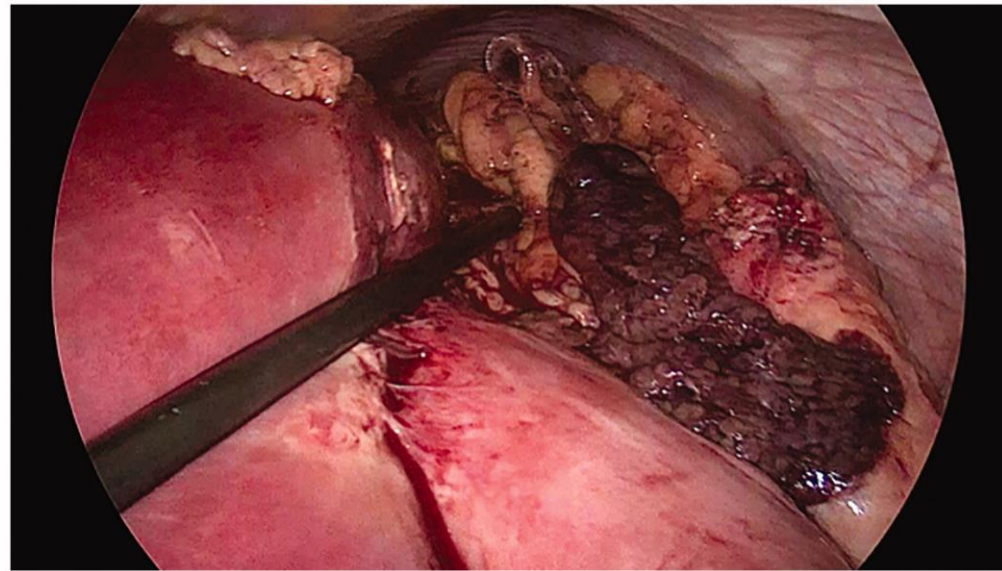
# Peritonitis: Management

**Surgical:**  
Laparoscopy? Laparotomy?



From Pr J. Himpens

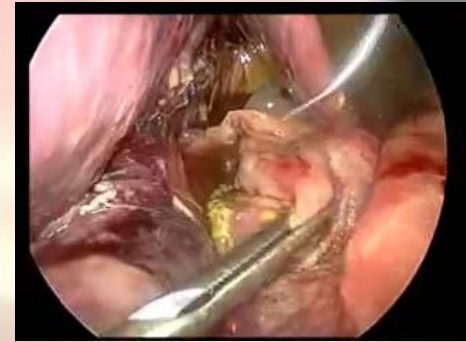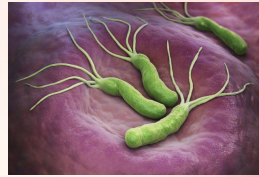
**Gastroraphy**



From Astrid Rycx a , Hendrik Maes b and Yves Van Nieuwenhove

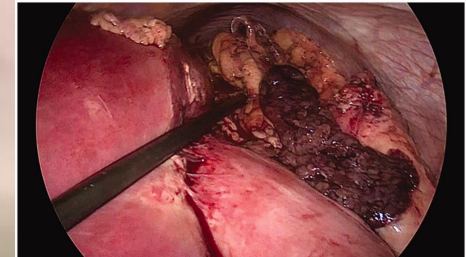
**Gastric remnant resection**

# Peritonitis: Causes



## ❑ Perforation

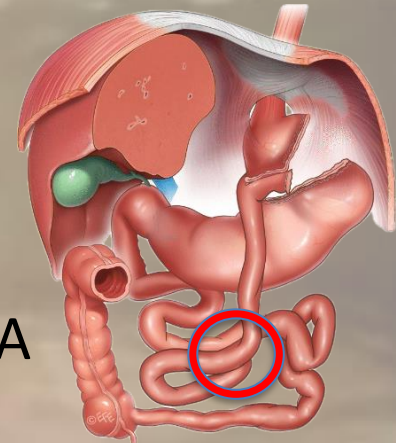
- NSAIDs or HP-induced **Marginal Ulcer**, Peptic Ulcerative Disease
- Energy device induced



## ❑ Ischemia and necrosis

- **Small Bowel Obstruction:** not rare

- Jejunojejunal anastomotic stricture
- Internal hernia: at or under the level of the JJA
- Accumulation of blood -> Remnant outlet obstruction, clots due to bleeding or cancer, unknown, hypercoagulable state...



## Gastric infarction following gastric bypass surgery

Patrick H Do <sup>1</sup>, Young S Kang <sup>1</sup>, Peter Cahill <sup>2</sup>

Affiliations + expand

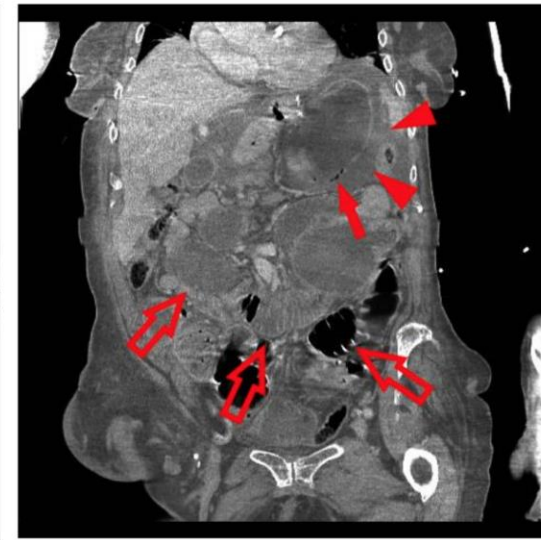
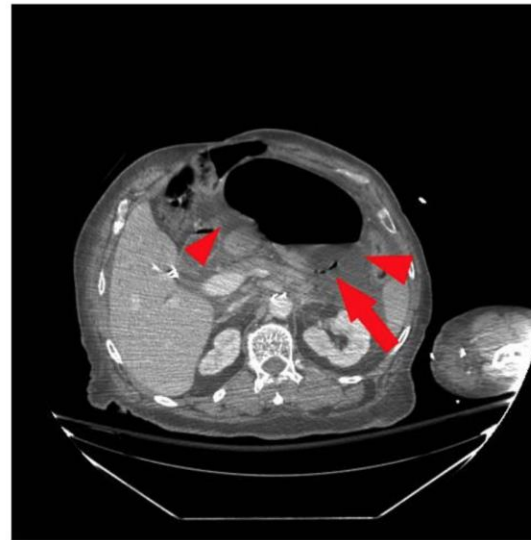
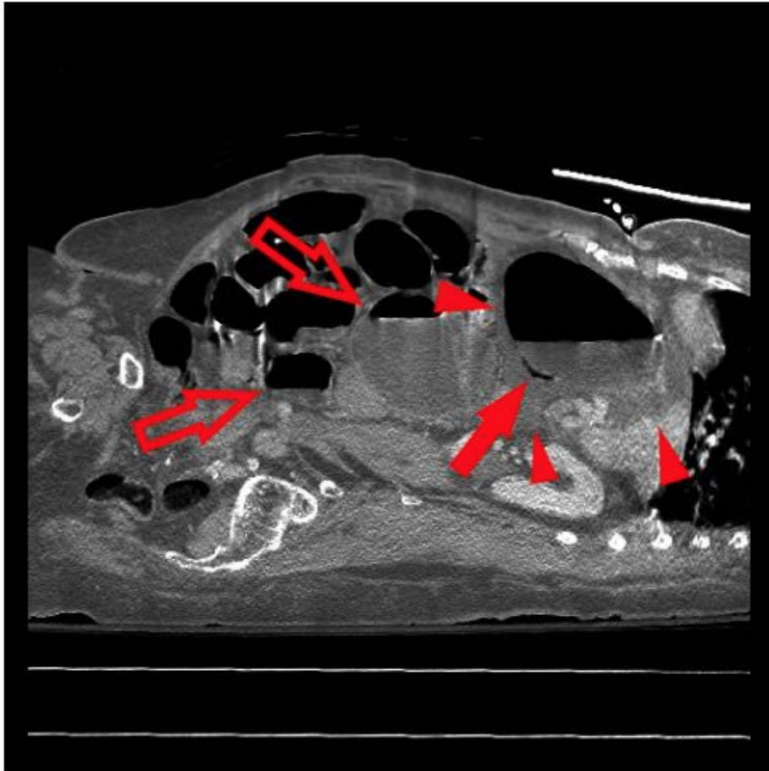PMID: 27200168 PMCID: PMC4861624 DOI: 10.3941/jrcr.v10i4.2280

## Cronkhite-Canada syndrome causing pouch outlet obstruction 5 years after roux-en-y gastric bypass

Ben Gys <sup>1</sup>, Joren Mertens <sup>1</sup>, Martin Ruppert <sup>1</sup>, Guy Hubens <sup>1</sup>

Affiliations + expand

PMID: 29202677 DOI: 10.1080/00015458.2017.1411556



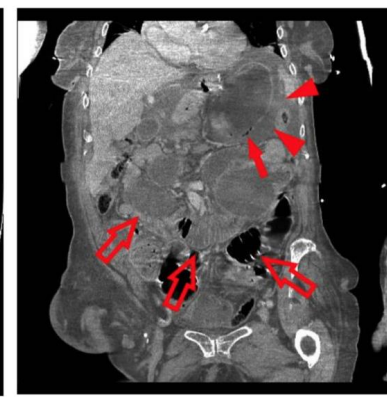
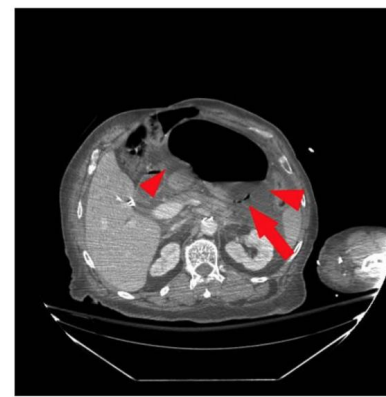
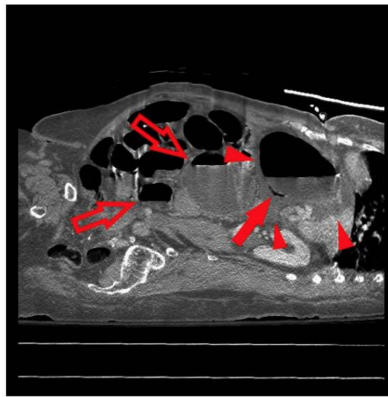
Case Reports > J Radiol Case Rep. 2016 Apr 30;10(4):16-22. doi: 10.3941/jrcr.v10i4.2280.  
eCollection 2016 Apr.

## Gastric infarction following gastric bypass surgery

Patrick H Do <sup>1</sup>, Young S Kang <sup>1</sup>, Peter Cahill <sup>2</sup>

Affiliations + expand

PMID: 27200168 PMCID: PMC4861624 DOI: 10.3941/jrcr.v10i4.2280

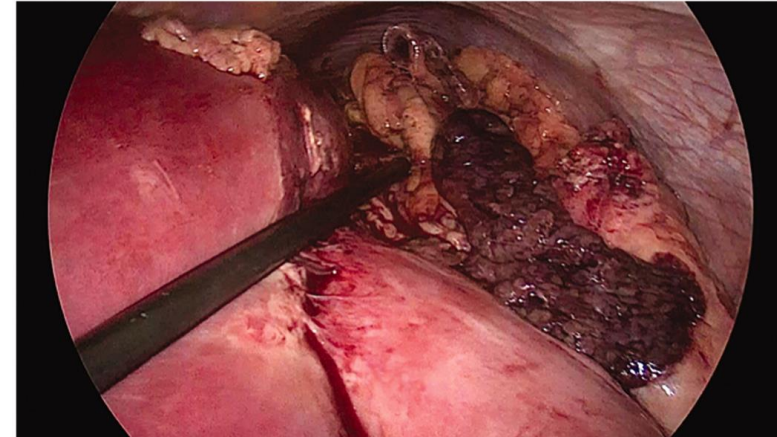


Case Reports > Acta Chir Belg. 2023 Feb;123(1):62-64.

doi: 10.1080/00015458.2021.1881335. Epub 2021 May 23.

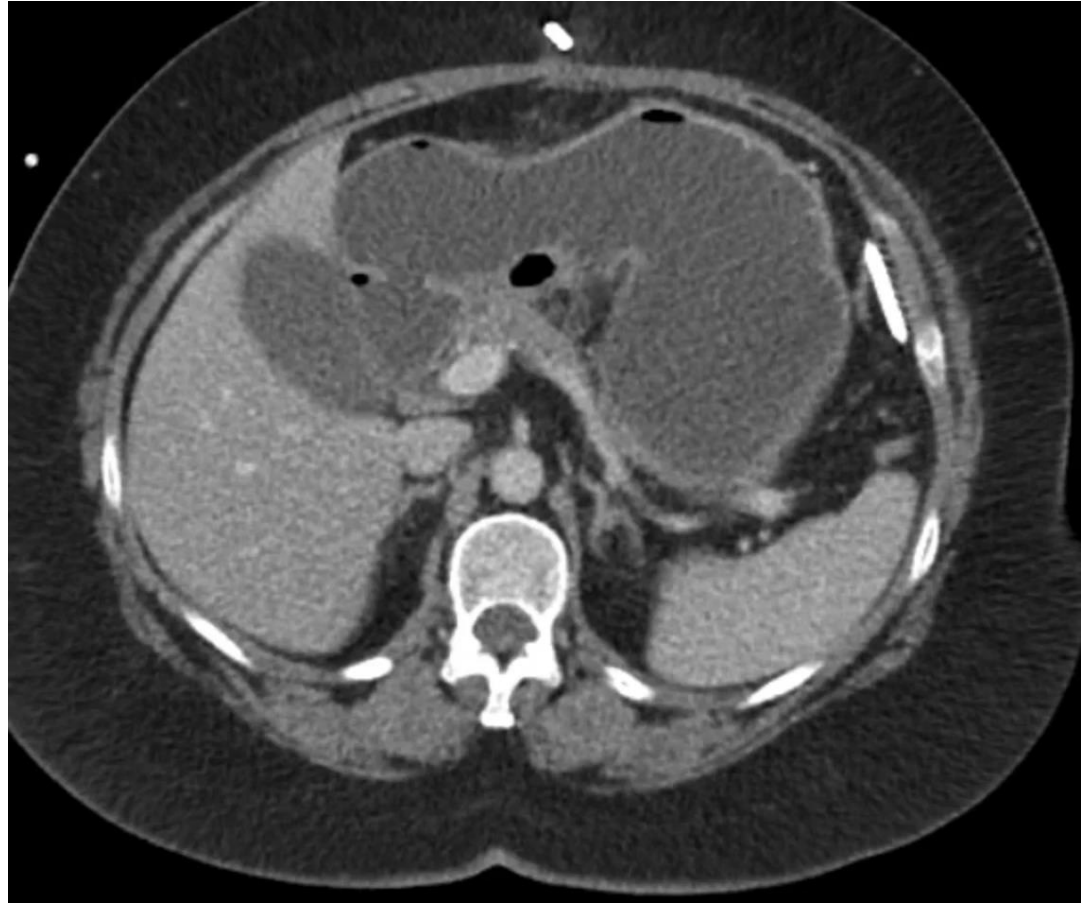
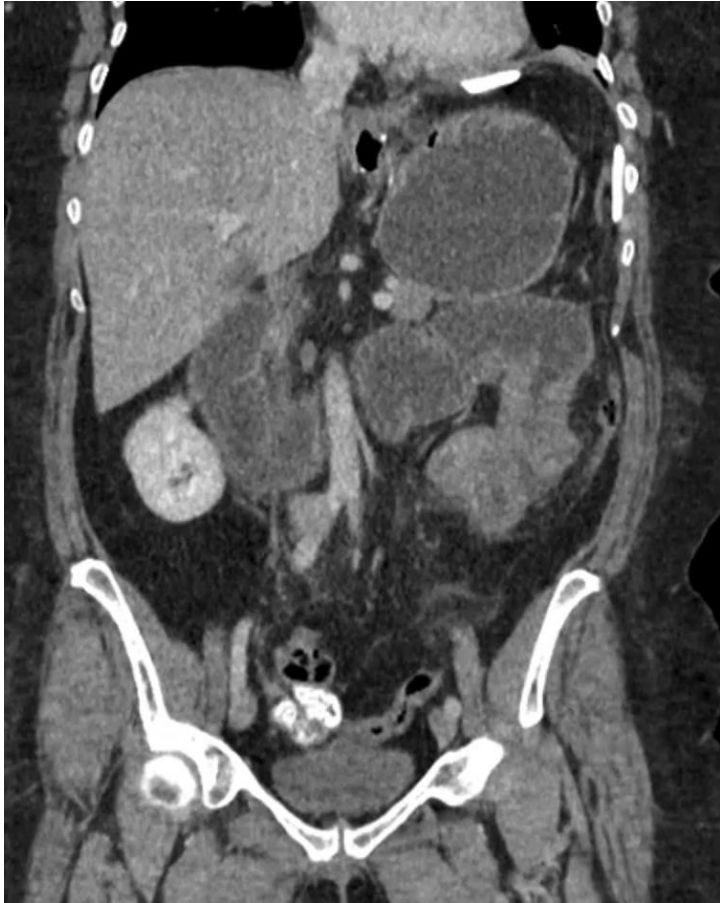## A rare complication of laparoscopic Roux-en-Y gastric bypass: case report of gastric remnant necrosis

Astrid Rycx <sup>1</sup>, Hendrik Maes <sup>2</sup>, Yves Van Nieuwenhove <sup>3</sup>



**Mortality rate of BURST Gastric Remnant  
because of necrosis  
>= 85%**

# Importance of Early Diagnosis



# Importance of Early (risk) Diagnosis:

Risk not to be underestimated: 0.03%?

Case Reports > Front Surg. 2019 Jan 30;6:3. doi: 10.3389/fsurg.2019.00003.  
eCollection 2019.

## Gastric Necrosis and Perforation Following Massive Gastric Dilatation in an Adolescent Girl: A Rare Cause of Acute Abdomen

Zlatan Zvizdic<sup>1</sup>, Asmir Jonuzi<sup>1</sup>, Aleksandra Djuran<sup>2</sup>, Semir Vranic<sup>3</sup>

Affiliations + expand

PMID: 30761307 PMCID: PMC6363666 DOI: 10.3389/fsurg.2019.00003

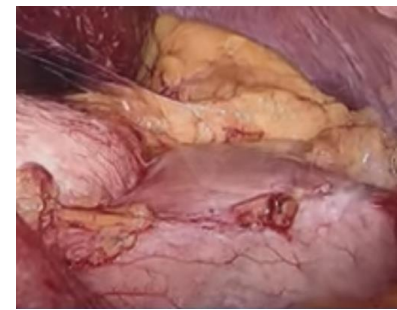> Abdom Imaging. 2007 Sep-Oct;32(5):613-8. doi: 10.1007/s00261-006-9086-z.

## Roux-en-Y gastric bypass: major complications

Marina Andrés<sup>1</sup>, Marta Pérez, José Roldán, Susana Borrueal, Javier de la Cruz Vigo, Javier Azpeitia, Elena Alvarez, Roberto Carrera, Verónica Muñoz

Affiliations + expand

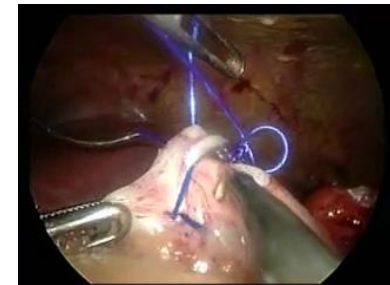
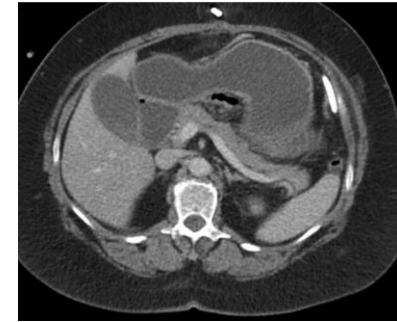PMID: 17874266 DOI: 10.1007/s00261-006-9086-z



**Mortality rate of burst G. Remnant because of necrosis  $\geq$  85%**

## Occlusion:

- ✓ Always check the Remnant: distention?
- ✓ Gastro**to**my: Emptying, assess G. R. viability
- ✓ Always adapt: occlusion -> Post op ileus..
- ✓ Gastro**sto**my: Decompression, early enteral feeding





**PERITONITIS**

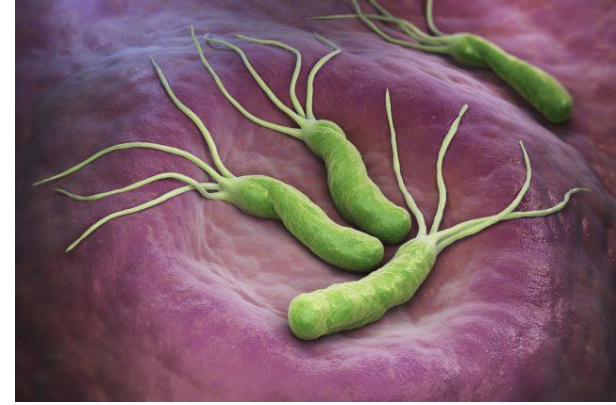**BLEEDING**



# BLEEDING



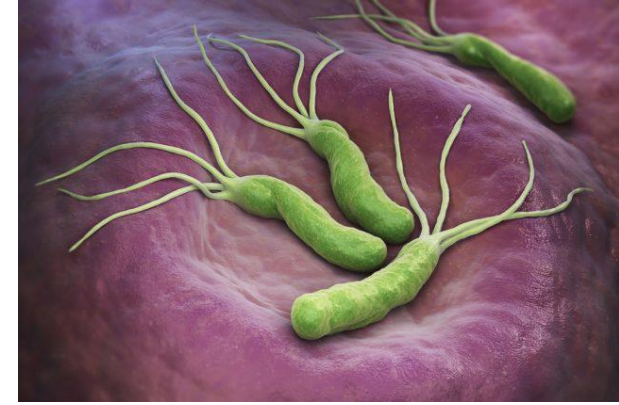# BLEEDING



❑ Life threatening

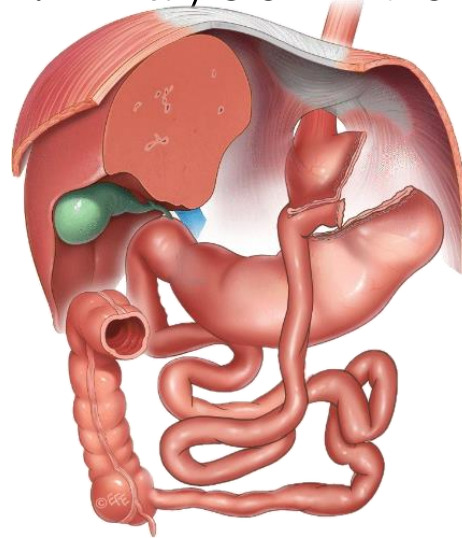
- **Risk Factors:** Smoking, Helicobacter Pylori infection, NSAIDs.
- **Symptoms:** Abdominal pain, gastrointestinal bleeding (e.g., hematemesis(???), **melena**), symptoms of an hemorrhagic shock: maybe not evident: no hematemesis unless...

# BLEEDING

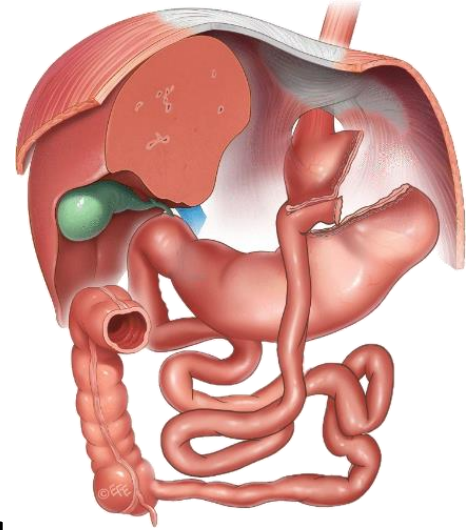


❑ Life threatening

- **Risk Factors:** Smoking, Helicobacter Pylori infection, NSAIDs.
- **Symptoms:** Abdominal pain, gastrointestinal bleeding (e.g., hematemesis(???), **melena**), symptoms of an hemorrhagic shock: maybe not evident: no **hematemesis** unless...



# Diagnostic Tools



- ❑ **Imaging:** CT scan with contrast, endoscopy, upper GI series.
- ❑ **Challenges:** Access the remnant via endoscopy
- ❑ **Laboratory f.:** Blood tests: acidosis, anemia

Case report

## Management of bleeding from gastric remnant after Roux-en-Y gastric bypass

Vichin Puri M.D.  , Annamalai Alagappan M.D., Moshe Rubin M.D., Stephen Merola M.D.

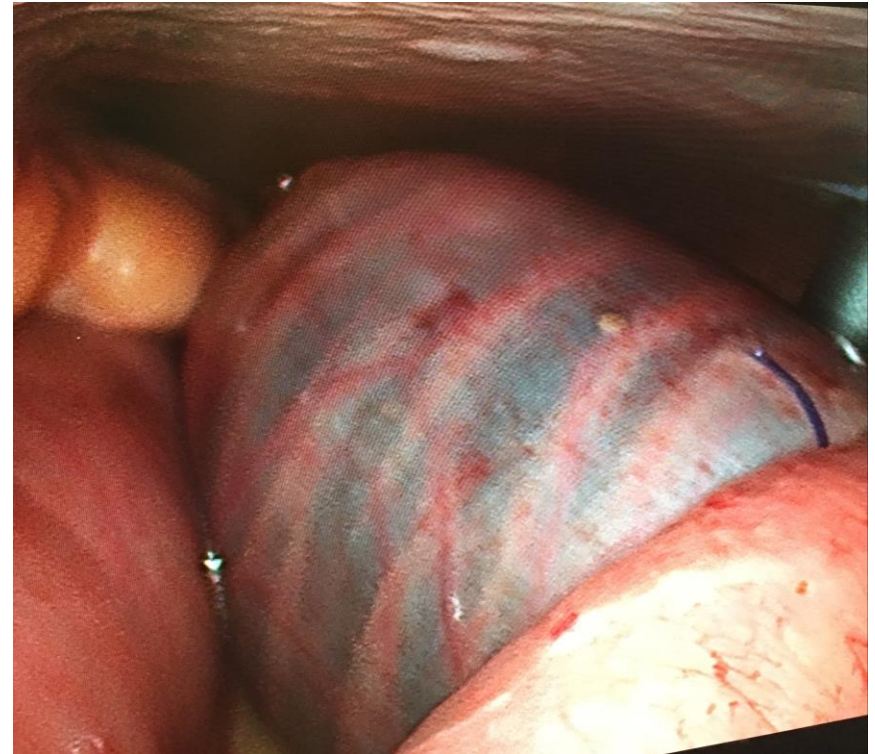
Case Reports > [Surg Obes Relat Dis.](#) 2017 May;13(5):e21–e23. doi: 10.1016/j.soard.2017.01.011.

Epub 2017 Jan 11.

### Resection of the excluded stomach due to severe bleeding immediately after Roux-en-Y gastric bypass in a patient with Lynch syndrome: a case report

Muhammad Ghanem <sup>1</sup>, Andre F Teixeira <sup>1</sup>, Muhammad A Jawad <sup>2</sup>

# EMERGENCY SURGERY

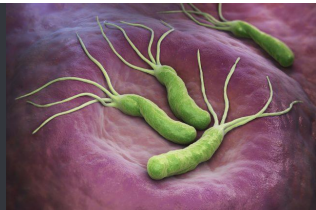

Laparoscopy ? / (->) Laparotomy ?



**RESECTION ?**

# Causes



- NSAIDs or HP-induced Ulcer, Peptic Ulcerative Disease

[Case Reports](#) > [Obes Surg.](#) 2010 Apr;20(4):523-5. doi: 10.1007/s11695-008-9629-1. Epub 2008 Jul 19.

## Failure of gastric bypass following several gastrointestinal hemorrhages

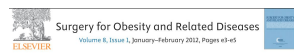Enrico Mozzi <sup>1</sup>, Ezio Lattuada, Marco Antonio Zappa, Ilaria Antonini, Francesco Andreoli, Sara Badiali, Giancarlo Roviato

## A delayed acute complication of bariatric surgery

### Gastric remnant haemorrhagic ulcer after Roux-en-Y gastric bypass

Patrascu, Stefan; Ponz, Carmen Balague<sup>1</sup>; Ananin, Sonia Fernandez; Soler, Eduardo M. Targarona<sup>1</sup>  
Author information

*Journal of Minimal Access Surgery* 14(1):p 68-70, Jan-Mar 2018. | DOI: 10.4103/jmas.JMAS\_148\_16



Case report

## Management of bleeding from gastric remnant after Roux-en-Y gastric bypass

Vickin Puril M.D. Anamoli Alagappan M.D., Moshe Rubin M.D., Stephen Mendis M.D.

[Case Reports](#) > [Surg Obes Relat Dis.](#) 2017 May;13(5):e21-e23. doi: 10.1016/j.soard.2017.01.011. Epub 2017 Jan 11.

## Resection of the excluded stomach due to severe bleeding immediately after Roux-en-Y gastric bypass in a patient with Lynch syndrome: a case report

Muhammad Ghanem <sup>1</sup>, Andre F Teixeira <sup>1</sup>, Muhammad A Jawad <sup>2</sup>

[Case Reports](#) > [Obes Surg.](#) 2002 Jun;12(3):404-7. doi: 10.1381/096089202321088255.

## Late gastrointestinal hemorrhage after gastric bypass

Scott C Braley <sup>1</sup>, Ninh T Nguyen, Bruce M Wolfe

Affiliations + expand

PMID: 12082897 DOI: 10.1381/096089202321088255

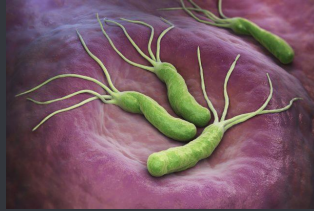[Case Reports](#) > [Surg Obes Relat Dis.](#) 2017 Aug;13(8):1451-1452.

doi: 10.1016/j.soard.2017.04.026. Epub 2017 Apr 27.

## Laparoscopic approach to a bleeding marginal ulcer fistulized to the gastric remnant in a patient post Roux-en-Y gastric bypass

Allison J Pang <sup>1</sup>, John Hagen <sup>2</sup>

# Causes



- NSAIDs or HP-induced Ulcer, Peptic Ulcerative Disease

- Tumors

Case Reports > [Obes Surg.](#) 2010 Apr;20(4):523-5. doi: 10.1007/s11695-008-9629-1. Epub 2008 Jul 19.

## Failure of gastric bypass following several gastrointestinal hemorrhages

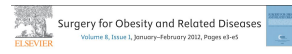Enrico Mozzi <sup>1</sup>, Ezio Lattuada, Marco Antonio Zappa, Ilaria Antonini, Francesco Andreoli, Sara Badiali, Giancarlo Roviato

## A delayed acute complication of bariatric surgery

### Gastric remnant haemorrhagic ulcer after Roux-en-Y gastric bypass

Patrascu, Stefan; Ponz, Carmen Balague<sup>1</sup>; Ananin, Sonia Fernandez; Soler, Eduardo M. Targarona<sup>1</sup>  
Author information

*Journal of Minimal Access Surgery* 14(1):p 68-70, Jan-Mar 2010. | DOI: 10.4103/jmas\_148\_16



Case report

## Management of bleeding from gastric remnant after Roux-en-Y gastric bypass

Vickin Puril M.D. Anamoli Alagappan M.D., Moshe Rubin M.D., Stephen Mendis M.D.

Case Reports > [Surg Obes Relat Dis.](#) 2017 May;13(5):e21-e23. doi: 10.1016/j.soard.2017.01.011. Epub 2017 Jan 11.

## Resection of the excluded stomach due to severe bleeding immediately after Roux-en-Y gastric bypass in a patient with Lynch syndrome: a case report

Muhammad Ghanem <sup>1</sup>, Andre F Teixeira <sup>1</sup>, Muhammad A Jawad <sup>2</sup>

Case Reports > [Obes Surg.](#) 2002 Jun;12(3):404-7. doi: 10.1381/096089202321088255.

## Late gastrointestinal hemorrhage after gastric bypass

Scott C Braley <sup>1</sup>, Ninh T Nguyen, Bruce M Wolfe

Affiliations + expand

PMID: 12082897 DOI: 10.1381/096089202321088255

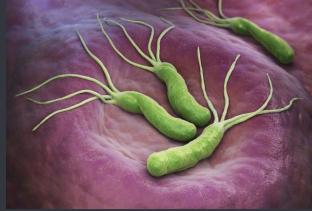Case Reports > [Surg Obes Relat Dis.](#) 2017 Aug;13(8):1451-1452.

doi: 10.1016/j.soard.2017.04.026. Epub 2017 Apr 27.

## Laparoscopic approach to a bleeding marginal ulcer fistulized to the gastric remnant in a patient post Roux-en-Y gastric bypass

Allison J Pang <sup>1</sup>, John Hagen <sup>2</sup>

# Causes



- NSAIDs or HP-induced Ulcer, Peptic Ulcerative Disease

- Tumors

- GGF

Case Reports > [Obes Surg.](#) 2010 Apr;20(4):523-5. doi: 10.1007/s11695-008-9629-1. Epub 2008 Jul 19.

## Failure of gastric bypass following several gastrointestinal hemorrhages

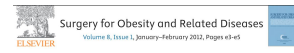Enrico Mozzi<sup>1</sup>, Ezio Lattuada, Marco Antonio Zappa, Ilaria Antonini, Francesco Andreoli, Sara Badiali, Giancarlo Roviato

## A delayed acute complication of bariatric surgery

### Gastric remnant haemorrhagic ulcer after Roux-en-Y gastric bypass

Patrascu, Stefan; Ponz, Carmen Balague<sup>1</sup>; Ananin, Sonia Fernandez; Soler, Eduardo M. Targarona<sup>1</sup>  
Author Information

*Journal of Minimal Access Surgery* 14(1):p 68-70, Jan-Mar 2018. | DOI: 10.4103/jmas.JMAS\_148\_16



Case report

## Management of bleeding from gastric remnant after Roux-en-Y gastric bypass

Vickin Ruff M.D., Anamoli Alagappan M.D., Moshe Rubin M.D., Stephen Mendis M.D.

Case Reports > [Surg Obes Relat Dis.](#) 2017 May;13(5):e21-e23. doi: 10.1016/j.soard.2017.01.011. Epub 2017 Jan 11.

## Resection of the excluded stomach due to severe bleeding immediately after Roux-en-Y gastric bypass in a patient with Lynch syndrome: a case report

Muhammad Ghanem<sup>1</sup>, Andre F Teixeira<sup>1</sup>, Muhammad A Jawad<sup>2</sup>

> [Surg Obes Relat Dis.](#) 2020 Mar;16(3):445-446. doi: 10.1016/j.soard.2019.11.016. Epub 2019 Dec 4.

## Emergency laparoscopic partial resection of the excluded stomach and gastric pouch in a gastric bypass patient with acute gastrogastic fistula bleeding

Jad M Abdelsattar<sup>1</sup>, Ian L McCulloch<sup>1</sup>, Salim Abunnaja<sup>2</sup>

Case Reports > [Obes Surg.](#) 2002 Jun;12(3):404-7. doi: 10.1381/096089202321088255.

## Late gastrointestinal hemorrhage after gastric bypass

Scott C Braley<sup>1</sup>, Ninh T Nguyen, Bruce M Wolfe

Affiliations + expand

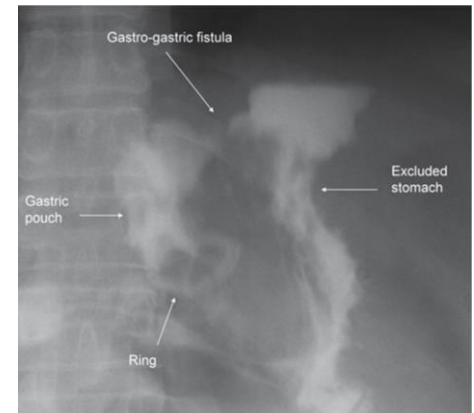
PMID: 12082897 DOI: 10.1381/096089202321088255

Case Reports > [Surg Obes Relat Dis.](#) 2017 Aug;13(8):1451-1452.

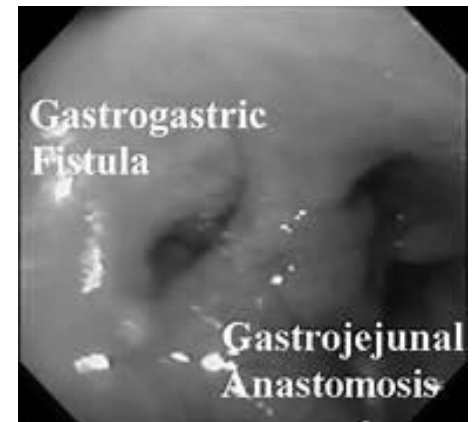doi: 10.1016/j.soard.2017.04.026. Epub 2017 Apr 27.

## Laparoscopic approach to a bleeding marginal ulcer fistulized to the gastric remnant in a patient post Roux-en-Y gastric bypass

Allison J Pang<sup>1</sup>, John Hagen<sup>2</sup>



Carla Barbosa Nonino



•Alcides José Branco Filho

# Causes



- NSAIDs or HP-induced Ulcer, Peptic Ulcerative Disease

- Tumors

- GGF

- Others

Case Reports > [Obes Surg.](#) 2010 Apr;20(4):523-5. doi: 10.1007/s11695-008-9629-1. Epub 2008 Jul 19.

## Failure of gastric bypass following several gastrointestinal hemorrhages

Enrico Mozzi<sup>1</sup>, Ezio Lattuada, Marco Antonio Zappa, Ilaria Antonini, Francesco Andreoli, Sara Badiali, Giancarlo Roviato

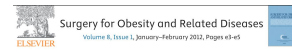## A delayed acute complication of bariatric surgery

### Gastric remnant haemorrhagic ulcer after Roux-en-Y gastric bypass

Patrascu, Stefan; Ponz, Carmen Balague<sup>1</sup>; Ananin, Sonia Fernandez<sup>2</sup>; Soler, Eduardo M. Targarona<sup>1</sup>

Author Information ⊕

*Journal of Minimal Access Surgery* 14(1):p 68-70, Jan-Mar 2018. | DOI: 10.4103/jmas.JMAS\_148\_16



Case report

### Management of bleeding from gastric remnant after Roux-en-Y gastric bypass

Vickin Ruff M.D., Anamoli Alagappan M.D., Moshe Rubin M.D., Stephen Mendis M.D.

Case Reports > [Surg Obes Relat Dis.](#) 2017 May;13(5):e21-e23. doi: 10.1016/j.soard.2017.01.011. Epub 2017 Jan 11.

## Resection of the excluded stomach due to severe bleeding immediately after Roux-en-Y gastric bypass in a patient with Lynch syndrome: a case report

Muhammad Ghanem<sup>1</sup>, Andre F Teixeira<sup>1</sup>, Muhammad A Jawad<sup>2</sup>

> [Surg Obes Relat Dis.](#) 2020 Mar;16(3):445-446. doi: 10.1016/j.soard.2019.11.016. Epub 2019 Dec 4.

## Emergency laparoscopic partial resection of the excluded stomach and gastric pouch in a gastric bypass patient with acute gastrogastic fistula bleeding

Jad M Abdelsattar<sup>1</sup>, Ian L McCulloch<sup>1</sup>, Salim Abunnaja<sup>2</sup>

Case Reports > [Obes Surg.](#) 2002 Jun;12(3):404-7. doi: 10.1381/096089202321088255.

## Late gastrointestinal hemorrhage after gastric bypass

Scott C Braley<sup>1</sup>, Ninh T Nguyen, Bruce M Wolfe

Affiliations + expand

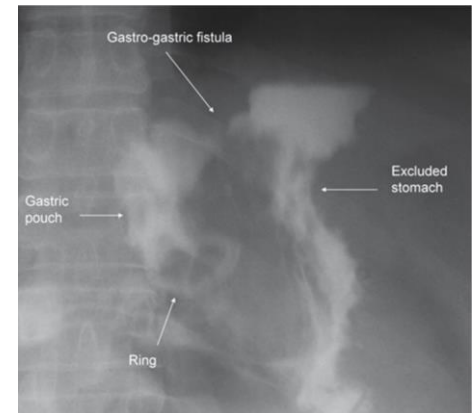
PMID: 12082897 DOI: 10.1381/096089202321088255

Case Reports > [Surg Obes Relat Dis.](#) 2017 Aug;13(8):1451-1452.

doi: 10.1016/j.soard.2017.04.026. Epub 2017 Apr 27.

## Laparoscopic approach to a bleeding marginal ulcer fistulized to the gastric remnant in a patient post Roux-en-Y gastric bypass

Allison J Pang<sup>1</sup>, John Hagen<sup>2</sup>

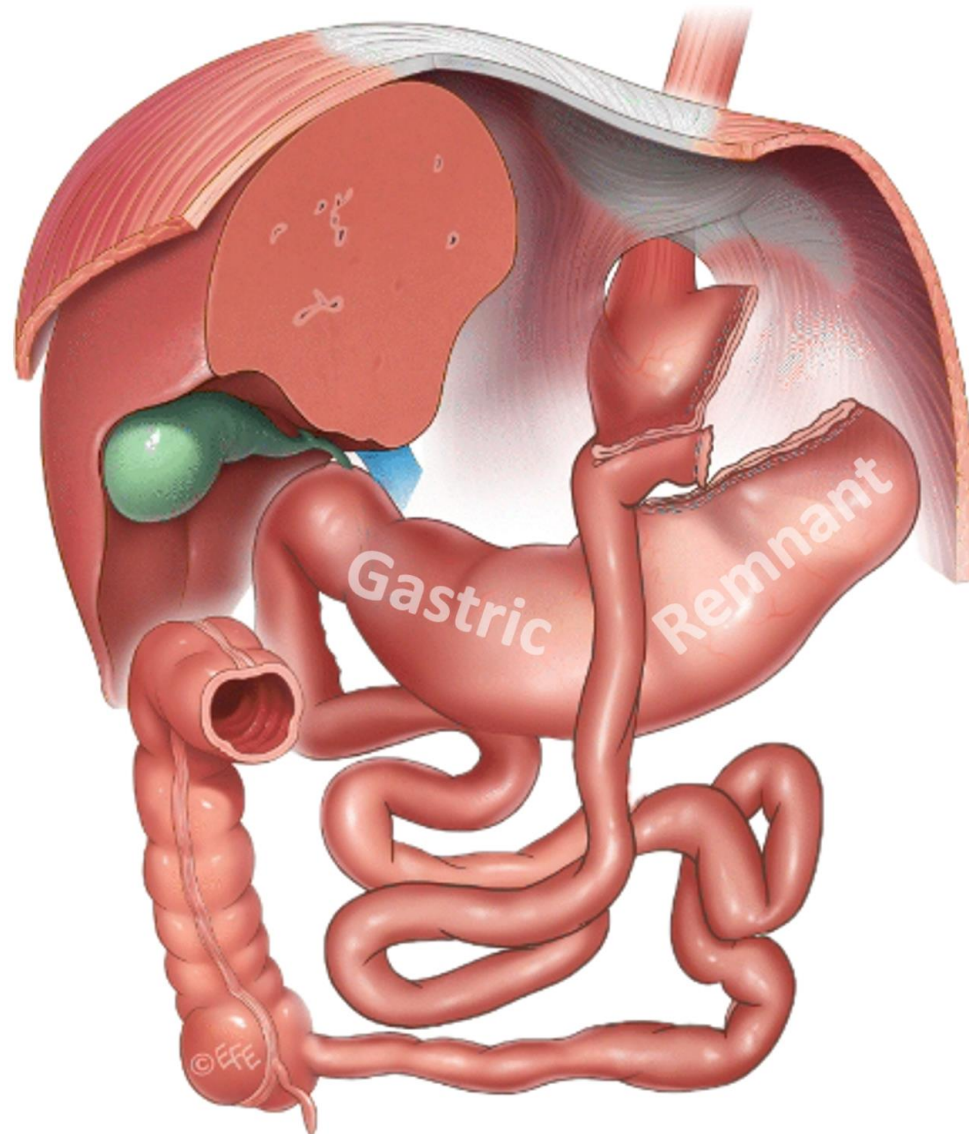


Carla Barbosa Nonino



•Alcides José Branco Filho

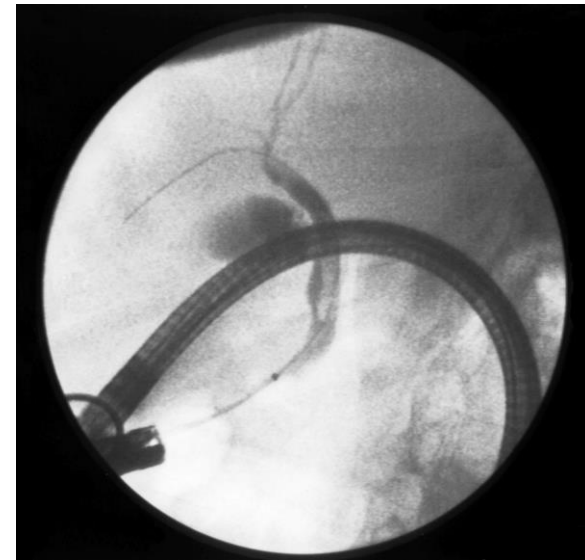
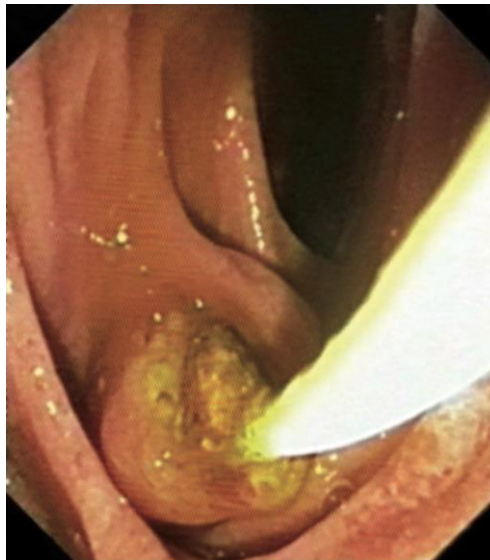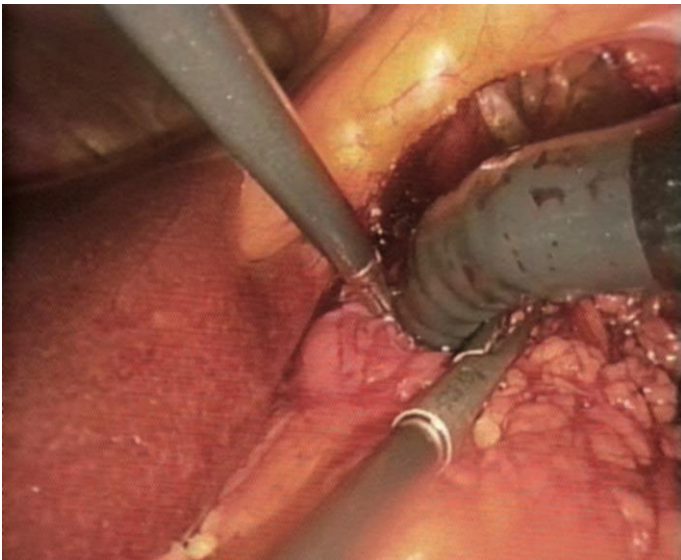
# Why is the Gastric Remnant worth keeping In Primary GBP?



# Why is the Gastric Remnant worth keeping In Primary GBP?

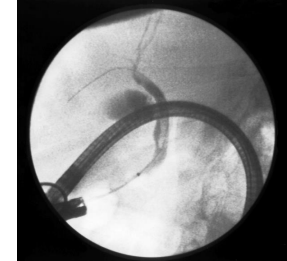
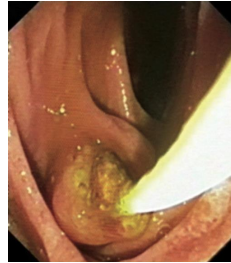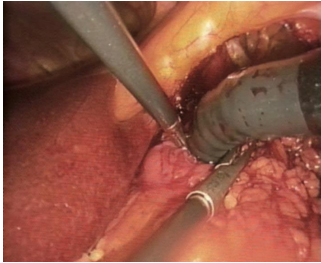
**YES**

- Endoscopic access: bile ducts...LTG ERCP



# Why is the Gastric Remnant worth keeping In Primary GBP?

□ Endoscopic access: bile ducts...LTG ERCP



□ Reversal

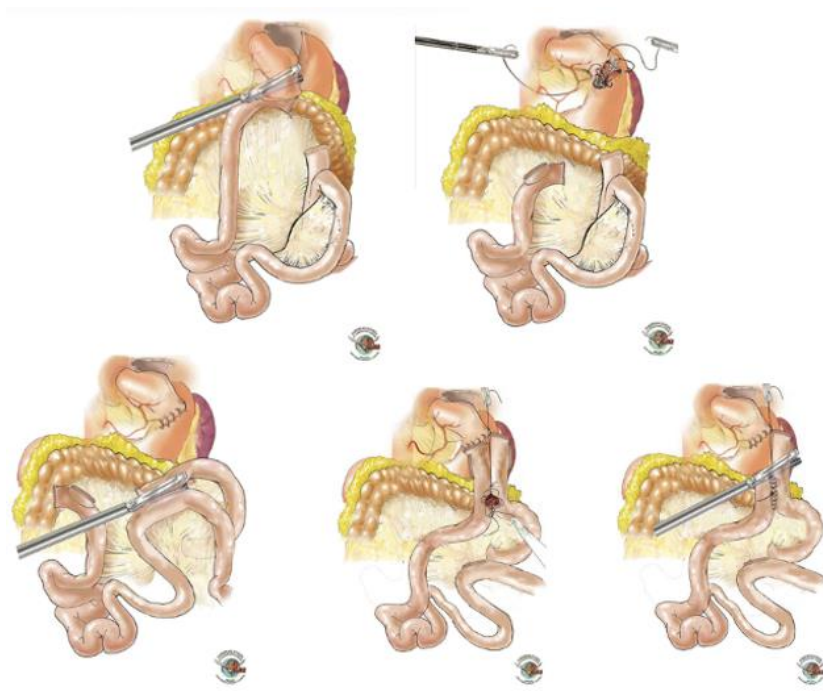
> [Obes Surg.](#) 2011 Aug;21(8):1289-95. doi: 10.1007/s11695-010-0252-6.

**Laparoscopic reconversion of Roux-en-Y gastric bypass to original anatomy: technique and preliminary outcomes**

Giovanni Dapri <sup>1</sup>, Guy Bernard Cadière, Jacques Himpens

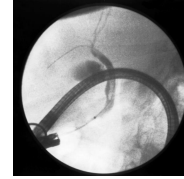
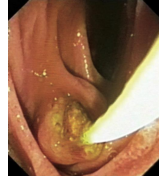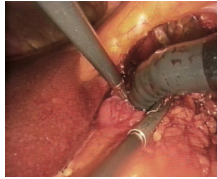
Affiliations + expand

PMID: 20824511 DOI: 10.1007/s11695-010-0252-6

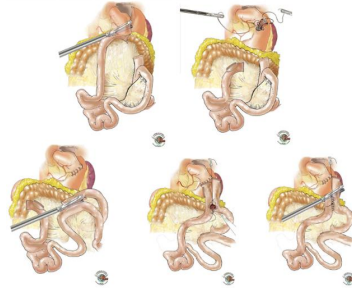


# Why is the Gastric Remnant worth keeping In Primary GBP?

□ Endoscopic access: bile ducts...LTG ERCP



□ Reversal



> [Obes Surg.](#) 2011 Aug;21(8):1289-95. doi: 10.1007/s11695-010-0252-6.

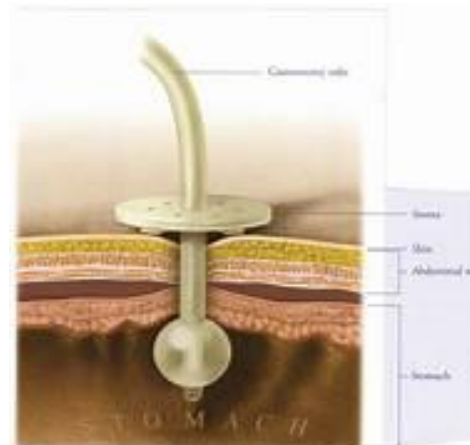
**Laparoscopic reconversion of Roux-en-Y gastric bypass to original anatomy: technique and preliminary outcomes**

Giovanni Dapri <sup>1</sup>, Guy Bernard Cadière, Jacques Himpens

Affiliations + expand

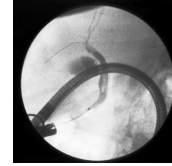
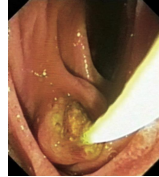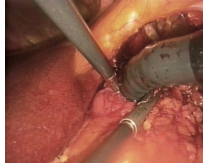
PMID: 20824511 DOI: 10.1007/s11695-010-0252-6

□ Discharge / Feeding

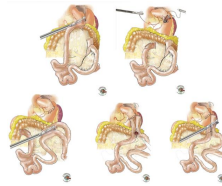


# Why is the Gastric Remnant worth keeping In Primary GBP?

- ❑ Endoscopic access: bile ducts...LTG ERCP



- ❑ Reversal



> *Obes Surg.* 2011 Aug;21(8):1289-95. doi: 10.1007/s11695-010-0252-6.

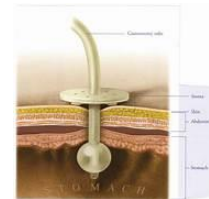**Laparoscopic reconversion of Roux-en-Y gastric bypass to original anatomy: technique and preliminary outcomes**

Giovanni Dapri <sup>1</sup>, Guy Bernard Cadlière, Jacques Himpens

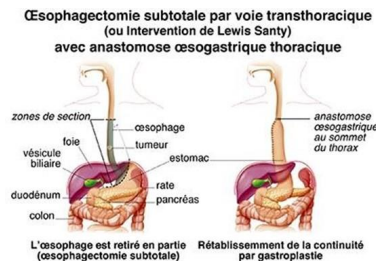
Affiliations + expand

PMID: 20824511 DOI: 10.1007/s11695-010-0252-6

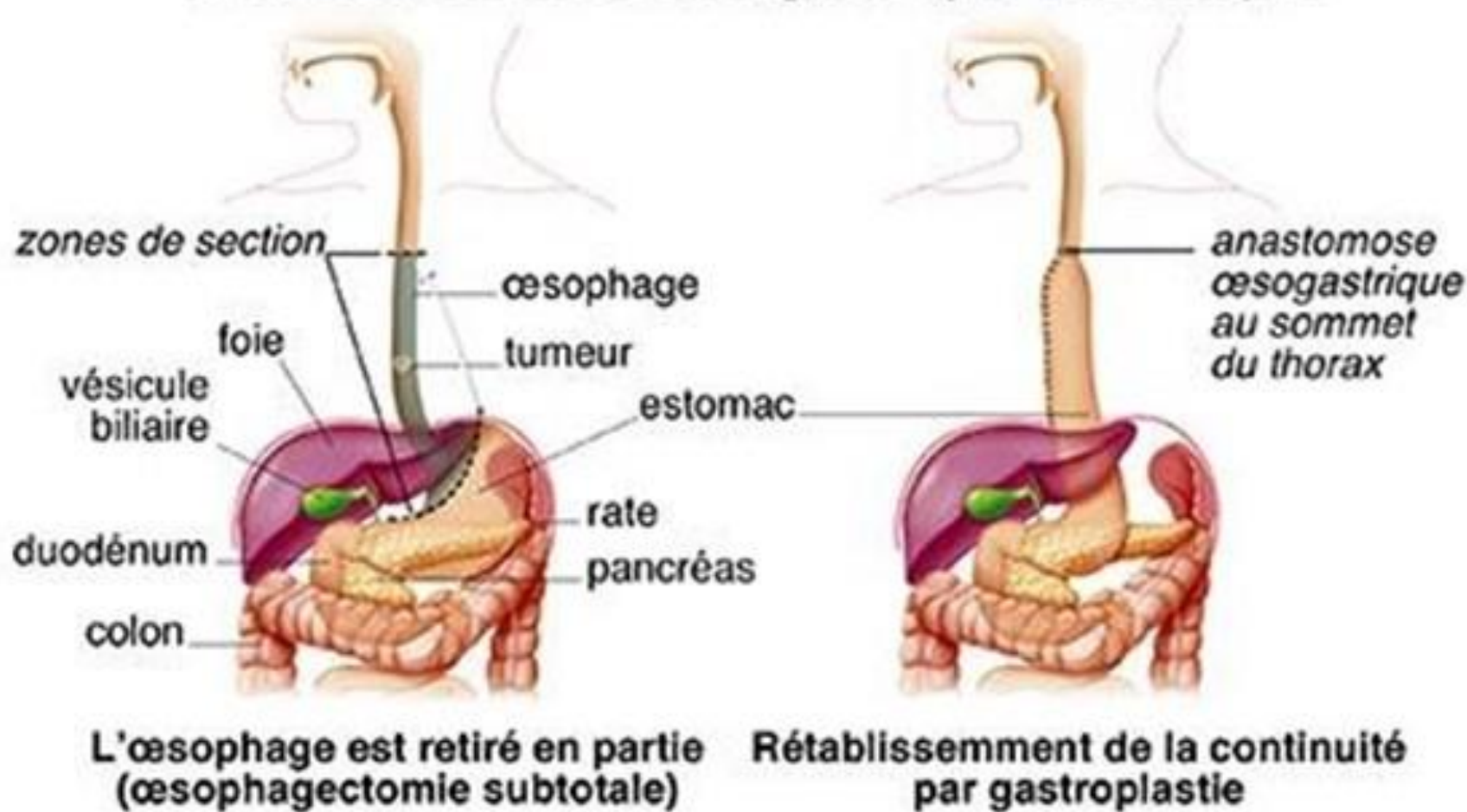
- ❑ Discharge / Feeding



- ❑ Plasty in case of Gastric Cardia cancer



# Œsophagectomie subtotale par voie transthoracique (ou Intervention de Lewis Santy) avec anastomose œsogastrique thoracique



# Resective Gastric Bypass

To be considered in selective situations:

- Ethnic groups
- Biermer anemia
- A. Intestinal metaplasia
- HP resistance

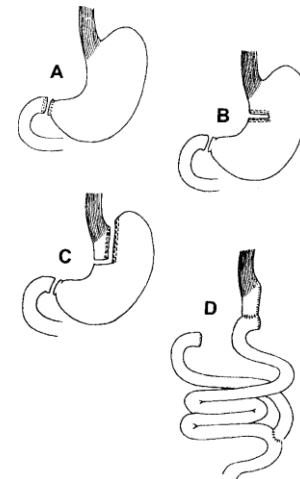
[Home](#) > [Journal of Gastrointestinal Surgery](#) > [Article](#)

## Results of gastric bypass plus resection of the distal excluded gastric segment in patients with morbid obesity

Published: January 2005

Volume 9, pages 121–131, (2005) [Cite this article](#)

[Attila Csendes M.D.](#), [Patricio Burdiles M.D.](#), [Karin Papapietro M.D.](#), [Juan Carlos Diaz M.D.](#), [Fernando Maluenda M.D.](#), [Ana Burgos M.D.](#) & [Jorge Rojas M.D.](#)



# Take-home message

❑ Early Risk Diagnosis:

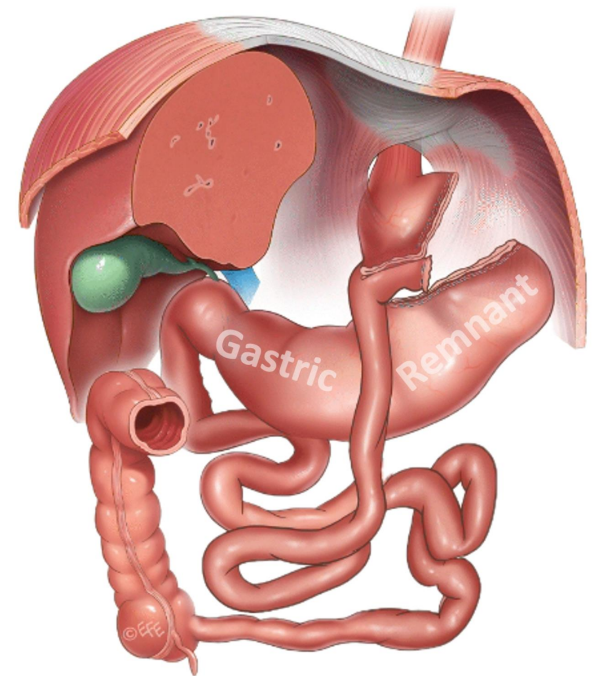
❑ Energy device induced burns!!!!!!

❑ Occlusion :

✓ Check the Remnant,

✓ Gastro**to**my, suction, assess viability

✓ Gastro**sto**my ? : Decompression (ileus) ; early feeding



Gracias



XXVIII IFSO World Congress  
9-12 September 2025 | Santiago, Chile

# Emergency Gastric Remnant Complications after Laparoscopic Roux-en-Y Gastric Bypass

*JPh M ma K MAGEMA, M.D.*

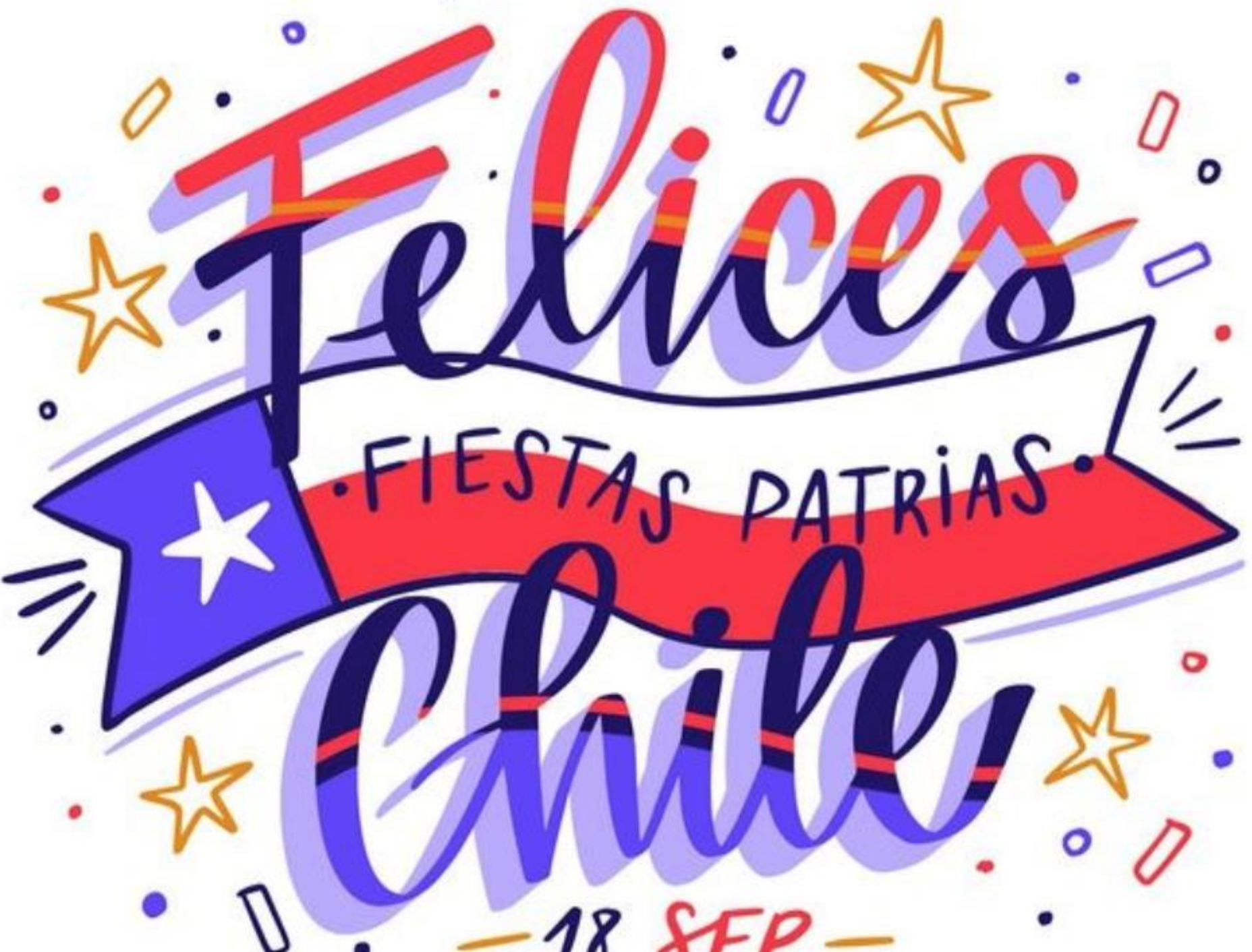*CHU UCL Namur, Dinant  
Belgium*

*jphmagma@yahoo.fr*

IFSO 2025  
Santiago

Combined Therapies, The Dawn of a New Era

[ifso2025.org](http://ifso2025.org)



FIESTAS PATRIAS.

— 18 SEP —

Gracias



XXVIII IFSO World Congress  
9-12 September 2025 | Santiago, Chile

# Emergency Gastric Remnant Complications after Laparoscopic Roux-en-Y Gastric Bypass

*JPh M ma K MAGEMA, M.D.*

*CHU UCL Namur, Dinant  
Belgium*

*jphmagma@yahoo.fr*

IFSO 2025  
Santiago

Combined Therapies, The Dawn of a New Era

[ifso2025.org](http://ifso2025.org)



# XXVIII IFSO World Congress

9-12 September 2025 | Santiago, Chile

## Emergency Gastric Remnant Complications after Laparoscopic Roux-en-Y Gastric Bypass

*JPh M ma K MAGEMA, M.D.*

*CHU UCL Namur, Dinant  
Belgium*

*jphmagma@yahoo.fr*

# IFSO 2025 Santiago

Combined Therapies, The Dawn of a New Era

[ifso2025.org](http://ifso2025.org)



XXVIII IFSO  
World Congress

9-12 September 2025  
Santiago, Chile

**No Disclosure**

# **Emergency** Gastric Remnant Complications after Laparoscopic Roux-en-Y Gastric Bypass

*JPh M ma K MAGEMA, M.D.*

*CHU UCL Namur, Dinant  
Belgium*

*[jphmagem@yahoofr](mailto:jphmagem@yahoofr)*



Congreso Internacional de Cirugía para la  
Obesidad y Enfermedades Metabólicas

**TIJUANA** JULIO 16-19 | **2025**

**Gracias**

**JPh MmaK MAGEMA, M.D.**

**COMPLICACIONES AGUDAS  
DEL REMANENTE GÁSTRICO  
DESPUÉS ROUX-EN-Y  
GASTRIC BYPASS**

**CHU UCL Namur, Dinant  
BÉLGICA**

**[jphmagem@yahoo.fr](mailto:jphmagem@yahoo.fr)**



Congreso Internacional de Cirugía para la  
Obesidad y Enfermedades Metabólicas

**TIJUANA** JULIO 16-19 | **2025**

# Gracias

**COMPLICACIONES AGUDAS  
DEL REMANENTE GÁSTRICO  
DESPUÉS ROUX-EN-Y  
GASTRIC BYPASS**

**JPh MmaK MAGEMA, M.D.**

**CHU UCL Namur, Dinant  
BÉLGICA**

**[jphmagem@yaho.fr](mailto:jphmagem@yaho.fr)**



Congreso Internacional de Cirugía para la  
Obesidad y Enfermedades Metabólicas

**TIJUANA** JULIO 16-19 | **2025**

# COMPLICACIONES AGUDAS DEL REMANENTE GÁSTRICO DESPUÉS ROUX-EN-Y GASTRIC BYPASS

**JPh MmaK MAGEMA, M.D.**

**CHU UCL Namur, Dinant  
BÉLGICA**

**[jphmagem@yaho.fr](mailto:jphmagem@yaho.fr)**



COLEGIO MEXICANO  
DE CIRUGÍA PARA LA OBESIDAD Y  
ENFERMEDADES METABÓLICAS

# Gracias

Dolor  
abdominal  
crónico después  
de RY-GBP

JPh MphK MAGEMA, M.D.

CHU UCL Namur, Dinant, Bélgica  
iphmagma@yahoo.fr

Congreso Internacional de Cirugía para  
Obesidad y Enfermedades Metabólicas

**TIJUANA** JULIO 16-19 | **2025**

26<sup>th</sup> BELGIAN SURGICAL WEEK

IMPACT OF **PATIENT** **SURGEON** GENDER  
ON THE OUTCOME OF SURGERY

## Emergency Gastric Remnant Complications after Laparoscopic Roux-en-Y Gastric Bypass

JPh. M.m.K. Magma, MD

CHU UCL NAMUR, site de Dinant

BELGIUM



**RBSS**  
Royal Belgian  
Society for Surgery

24<sup>TH</sup> - 26<sup>TH</sup> APRIL, 2025  
THERMAE PALACE  
OSTEND

# Prevention and Long-Term Follow-Up

- ❑ **Prevention:** Importance of patient education on risk factors, regular follow-up, and avoidance of NSAIDs.
- ❑ **Follow-Up:** Regular endoscopic monitoring, imaging if symptomatic, lifestyle modifications.

Case Reports > J Radiol Case Rep. 2016 Apr 30;10(4):16-22. doi: 10.3941/jrcr.v10i4.2280.

eCollection 2016 Apr.

## Gastric infarction following gastric bypass surgery

Patrick H Do<sup>1</sup>, Young S Kang<sup>1</sup>, Peter Cahill<sup>2</sup>

Affiliations + expand

PMID: 27200168 PMCID: PMC4861624 DOI: 10.3941/jrcr.v10i4.2280

Case Reports > Surg Obes Relat Dis. 2017 Aug;13(8):1451-1452.

doi: 10.1016/j.soard.2017.04.026. Epub 2017 Apr 27.

## Laparoscopic approach to a bleeding marginal ulcer fistulized to the gastric remnant in a patient post Roux-en-Y gastric bypass

Allison J Pang<sup>1</sup>, John Hagen<sup>2</sup>

## A delayed acute complication of bariatric surgery

### Gastric remnant haemorrhagic ulcer after Roux-en-Y gastric bypass

Patrascu, Stefan; Ponz, Carmen Balague<sup>1</sup>; Ananin, Sonia Fernandez

Author Information

Journal of Minimal Access Surgery 14(1):p 68-70, Jan-Mar 2018. | DOI: 10.1007/s00261-006-9086-z

Case Reports > Acta Chir Belg. 2023 Feb;123(1):62-64.

doi: 10.1080/00015458.2021.1881335. Epub 2021 May 23.

## A rare complication of laparoscopic Roux-en-Y gastric bypass: case report of gastric remnant necrosis

Astrid Rycx<sup>1</sup>, Hendrik Maes<sup>2</sup>, Yves Van Nieuwenhove<sup>3</sup>

Case Reports > Obes Surg. 2002 Jun;12(3):404-7. doi: 10.1381/096089202321088255.

## Late gastrointestinal hemorrhage after gastric bypass

Scott C Braley<sup>1</sup>, Ninh T Nguyen, Bruce M Wolfe

Affiliations + expand

PMID: 12082897 DOI: 10.1381/096089202321088255

Case Reports > Acta Chir Belg. 2019 Feb;119(1):56-58. doi: 10.1080/00015458.2017.1411556.

Epub 2017 Dec 5.

## Cronkhite-Canada syndrome causing pouch outlet obstruction 5 years after roux-en-y gastric bypass

Ben Gys<sup>1</sup>, Joren Mertens<sup>1</sup>, Martin Ruppert<sup>1</sup>, Guy Hubens<sup>1</sup>

Affiliations + expand

PMID: 29202677 DOI: 10.1007/s00261-006-9086-z

Journal of Minimal Access Surgery 14(1):p 68-70, Jan-Mar 2018. | DOI: 10.1007/s00261-006-9086-z.

## Roux-en-Y gastric bypass: major complications

Marina Andrés<sup>1</sup>, Marta Pérez, José Roldán, Susana Borrue, Javier de la Cruz Vigo, Javier Azpeitia, Elena Alvarez, Roberto Carrera, Verónica Muñoz

Affiliations + expand

PMID: 17874266 DOI: 10.1007/s00261-006-9086-z

Case Reports > Front Surg. 2019 Jan 30;6:3. doi: 10.3389/fsurg.2019.00003.

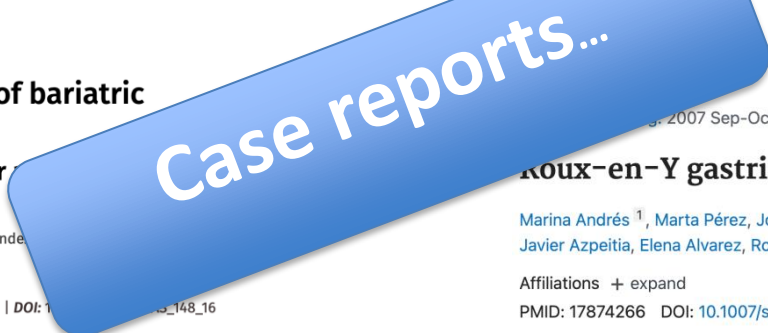eCollection 2019.

## Gastric Necrosis and Perforation Following Massive Gastric Dilatation in an Adolescent Girl: A Rare Cause of Acute Abdomen

Zlatan Zvizdic<sup>1</sup>, Asmir Jonuzi<sup>1</sup>, Aleksandra Djuran<sup>2</sup>, Semir Vranic<sup>3</sup>

Affiliations + expand

PMID: 30761307 PMCID: PMC6363666 DOI: 10.3389/fsurg.2019.00003



# IBC-UNIVERSITY OF OXFORD WORLD CONGRESS

University of Oxford, United Kingdom

SEPTEMBER 17-19, 2024

[www.ibcclub.org](http://www.ibcclub.org)

## Emergency Gastric Remnant Complications after Laparoscopic Roux-en-Y Gastric Bypass

JPh. M.m.K. Magera, MD

CHU UCL NAMUR, site de Dinant

BELGIUM



# IBC-UNIVERSITY OF OXFORD WORLD CONGRESS

University of Oxford, United Kingdom

SEPTEMBER 17-19, 2024

[www.ibcclub.org](http://www.ibcclub.org)

## Emergency Gastric Remnant Complications after Laparoscopic Roux-en-Y Gastric Bypass

JPh. M.m.K. Magera, MD

CHU UCL NAMUR, site de Dinant

BELGIUM



# IBC-UNIVERSITY OF OXFORD WORLD CONGRESS

University of Oxford, United Kingdom

SEPTEMBER 17-19, 2024

[www.ibcclub.org](http://www.ibcclub.org)