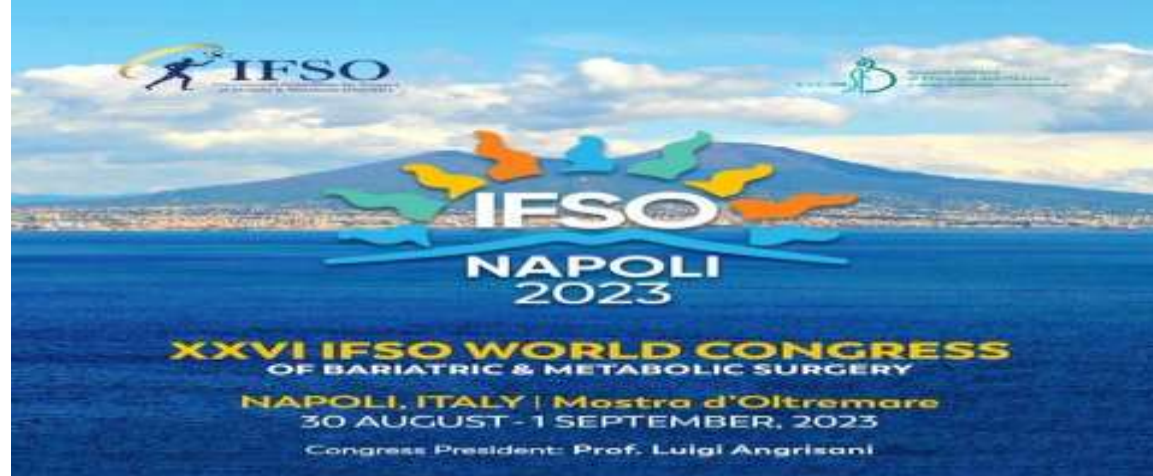



# Conversion to Nissen sleeve in a single stage for Barrett and non-responder weight loss after gastric

Aiman Ismaeil, Bruno Dillemans



# Clinical Presentation

- **Patient:** (65, F)
- **Medical History:** (Major reflux esophagitis with Barrett)
- **Surgical History:**
  - Hysterectomy      - Ovariectomy
  - 2017: Breast carcinoma => Tumorectomy with (Radio+ hormonal+ adjuvant chemo) therapy
  - 2020: Breast Neurofibroma => Medication: Hygroton, Letrozole, Serlain and Urolina
- **Bariatric surgery History:**    - 2002: Gastric Band      Weight: 80 kg => 55 kg

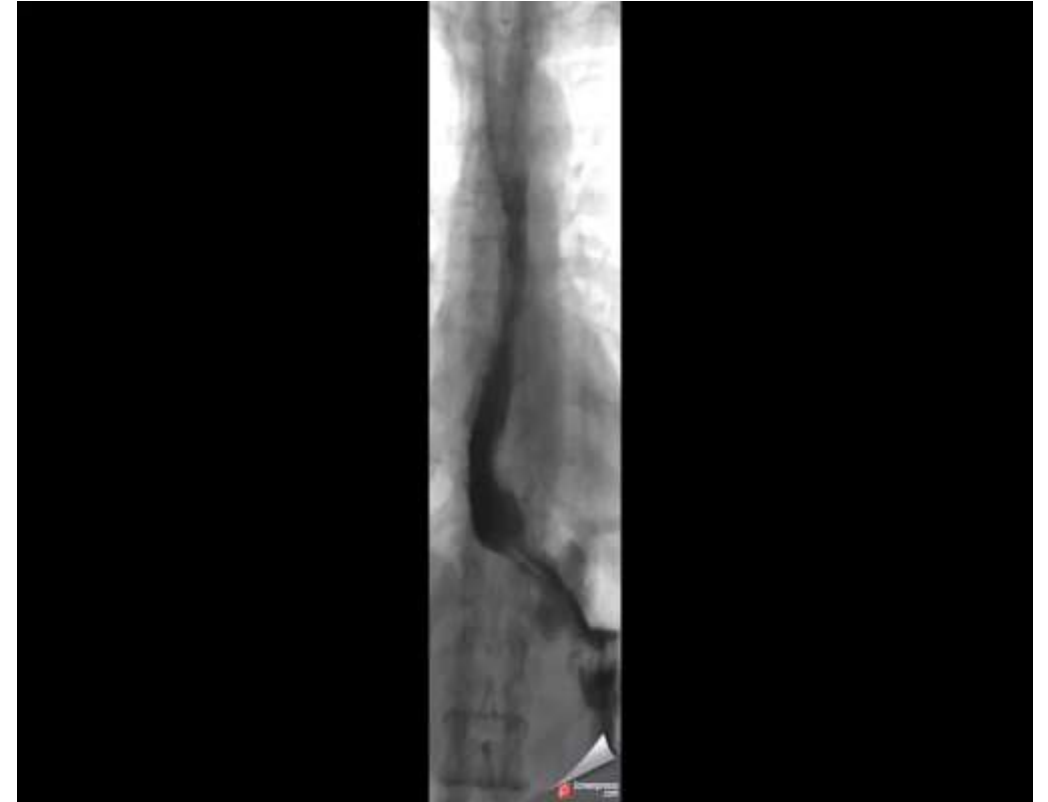# Preoperative Examination

## Current History

- Psychological problems due to weight regain  
=> Weight 79.200 kg, BMI 33.2
- Reflux esophagitis
- Dyspnea, OSAS
- Back and Knee pain

# Preoperative Examination

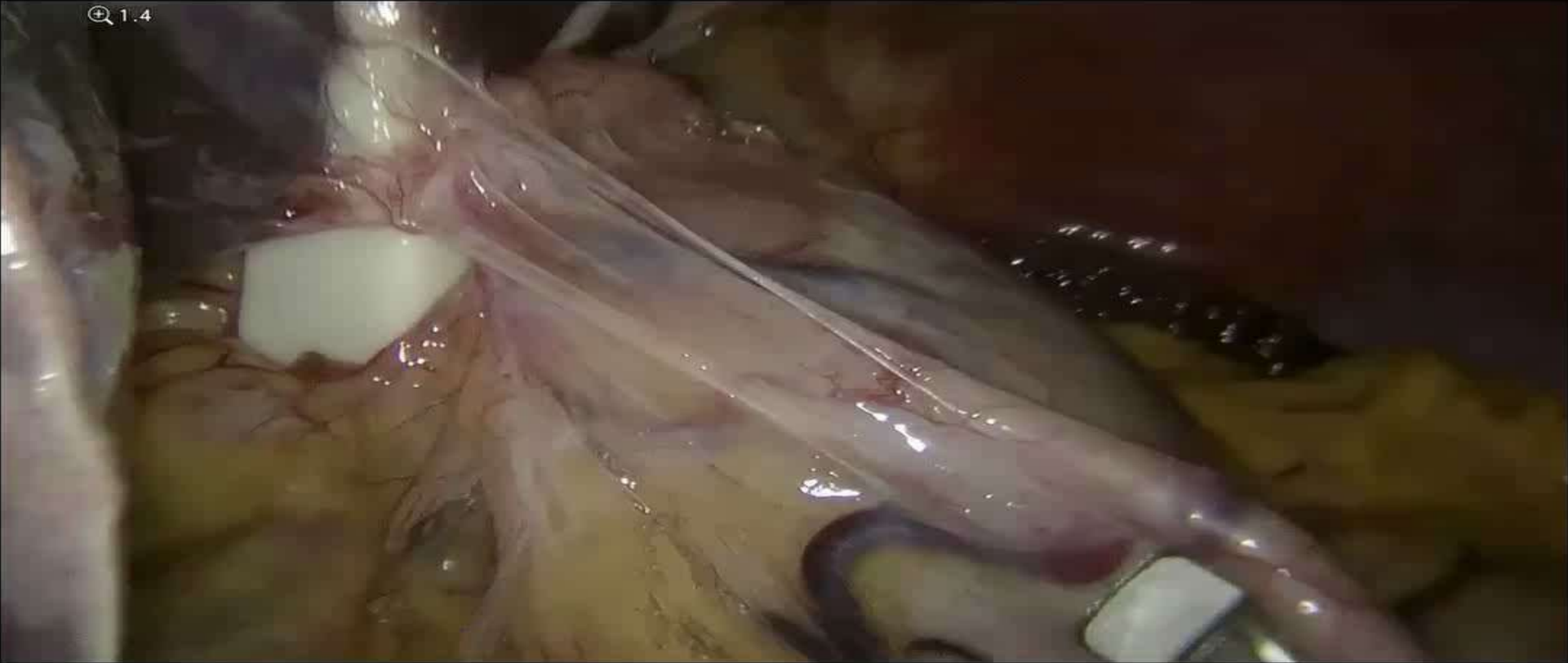
- **Upper GI series:**
  - Band slippage
  - Delayed contrast passage through EGJ with contrast stasis and 2ry widening in the distal esophagus
  - Tertiary contractions



- **Gastroscopy**

- Gastric band appears to be at the level of fundus/cardia
- Barrett esophagus, no active esophagitis, no circular Barrett

- **Operative plan:** Laparoscopic removal of the gastric band and conversion to Nissen Sleeve + cruroplasty



# Follow-up

- **Follow-up 6 weeks**

- Weight : pre 79.200 kg, => post 68 kg (-11.2 kg)
- Heartburn completely resolved
- No dysphagia complaints, the food went smoothly
- Stopped PPI drugs
- Performed daily sports



Thank you for your attention

