

# Closure of Hiatal Hernia with esophageal fixation. Durability?

## R-PEL



Catalin Copaescu, MD, PhD

PONDERAS ACADEMIC HOSPITAL

Bucharest, Romania

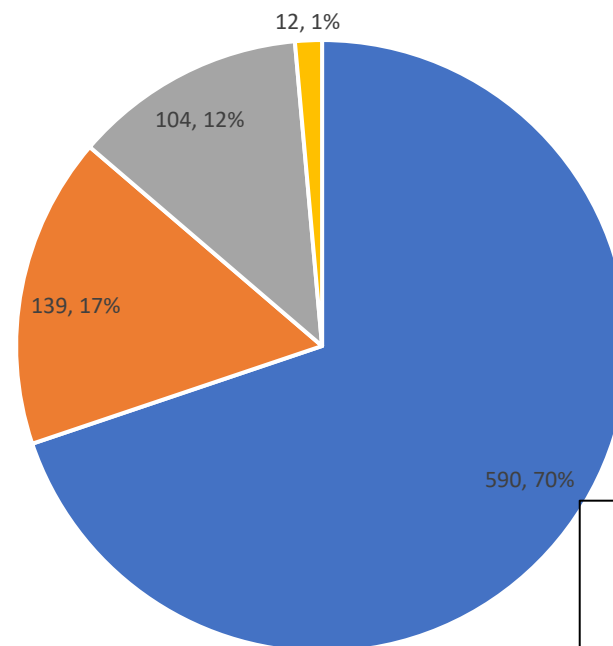


**PONDERAS**  
ACADEMIC HOSPITAL

# Disclosures

Executive Director of Surgical Training Institute involved in **endoscopic surgery training and educational programs** together: Karl Storz, Medtronic, Ethicon-JJ, BARD

Bariatric Surgery activity in 2022 ( 845 pts)



Bariatric Surgery Experience 12000+

■ LSG ■ GBP ■ Revisional ■ Others



IFSO 2023

# Background

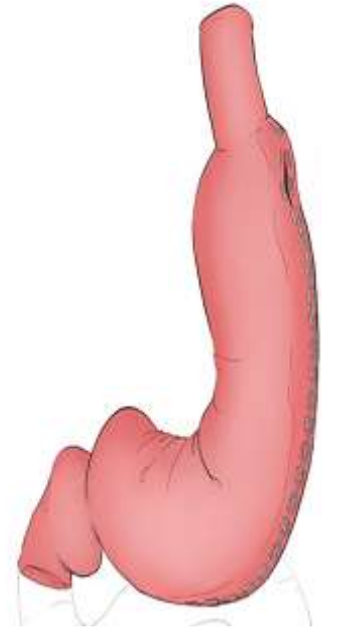
- GERD & hiatal hernia (HH) are expected in >70% and > 40% of the bariatric surgery candidates (1,2)
- Laparoscopic Sleeve Gastrectomy (LSG) is the most frequently performed bariatric procedure
- We already solved the issue of the surgical technique to fashion a “perfect sleeve”

1. Che F, Nguyen B, Cohen A, Nguyen NT (2013) Prevalence of hiatal hernia in the morbidly obese. Surg Obes Relat Dis 9:920–924

2. Sharara AI, Rustom LBO, Bou Daher H, Rimmani HH, Shayto RH, Minhem M et al (2019) Prevalence of gastroesophageal reflux and risk factors for erosive esophagitis in obese patients considered for bariatric surgery. Dig Liver Dis 51(10):1375–1379

# Background - “perfect sleeve”

- Two challenging issues :
  - The rate% of unsolved & “de-novo” GERD after SG (NOT Barrett)
  - Uncontrolled phenomenon of postoperative Intrathoracic Migration (ITM) and HH (after RYGBP as well)
- Questions:
  - Is it the SG concept?
  - Are the issues linked?
  - Is it the unaddressed HH?
    - limited explorations, HHR only ranging from 2.4 to 18,5%



# Solutions to prevent & control the ITM of SG

- Fundoplication & Sleeve Gastrectomy (N-Sleeve, D-Sleeve, R-Sleeve)
  - Magnetic sphincter augmentation (LINX)
  - Teres Ligamentum Cardiopexy (Narbona-Arnau)
  - Modified Hill's Gastropexy
  - Fixation to the Prepancreatic Fascia
  - Omentopexy
- Nocca et al.2016,  
DelGenio et al.,2020,  
Olmi et al., 2020,  
Desart K, et al 2015,  
Gálvez-Valdovinos R, et al. 2015  
Sánchez-Pernaute A, et al 2016
- **AIM: Simple, efficient, low morbidity, cost-effective, largely accepted procedure**

# Solutions to prevent & control the ITM

- Fundoplication & Sleeve Gastrectomy (N-Sleeve, D-Sleeve, R-Sleeve)
- Magnetic sphincter augmentation (LINX)
- Teres Ligamentum Cardiopexy (N)
- Modified Hill's Gastropexy
- Fixation to the Prepancreatic Fascia
- Omentopexy

Surgical Endoscopy (2023) 37:3747–3759  
<https://doi.org/10.1007/s00464-022-09829-z>



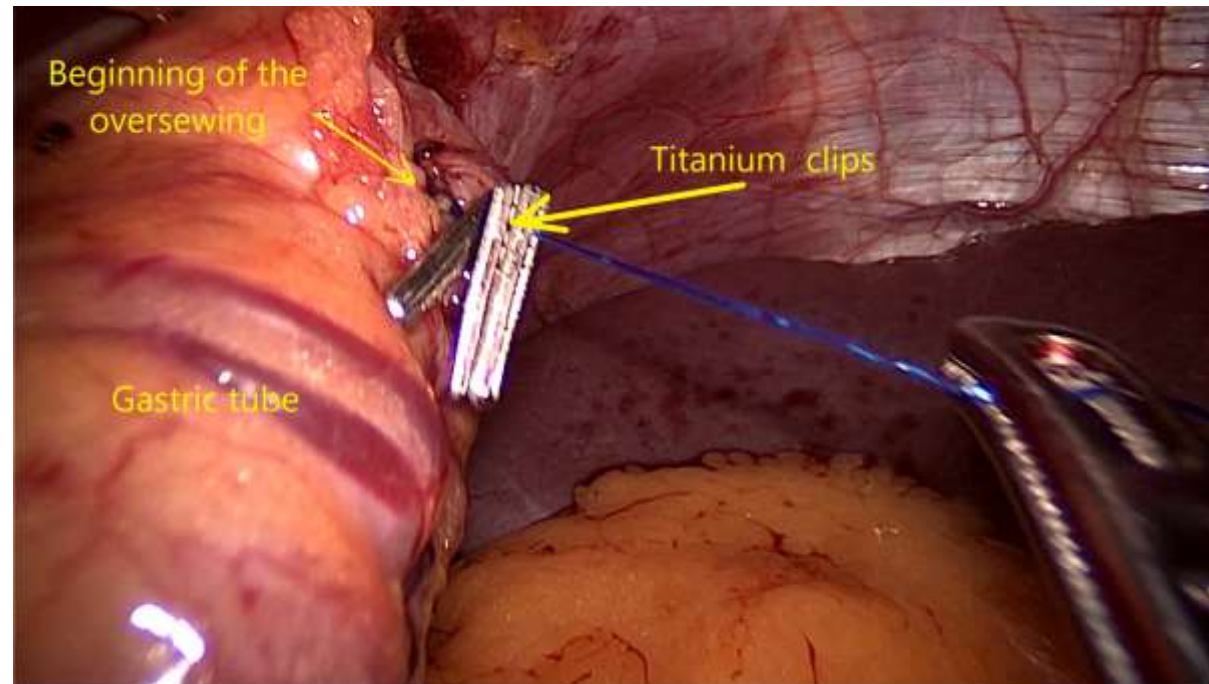
**Reconstruction of the phreno-esophageal ligament (R-PEL) prevents the intrathoracic migration (ITM) after concomitant sleeve gastrectomy and hiatal hernia repair**

I. Hutopila<sup>1,2</sup> · M. Ciocoiu<sup>3</sup> · L. Paunescu<sup>3</sup> · C. Copaescu<sup>1,4,5</sup> 

- **Reconstruction of the phreno-esophageal ligament (R-PEL)**

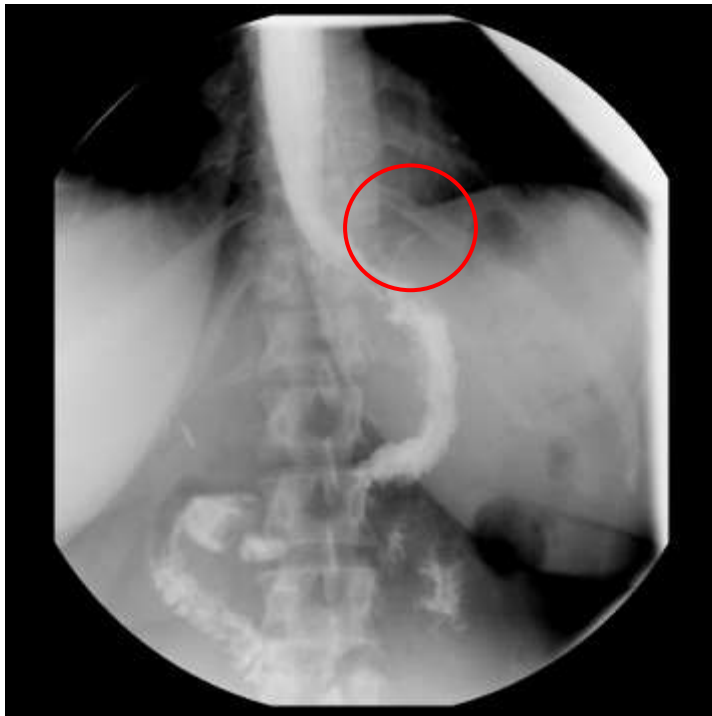# R-PEL – Surgical Protocols (PAH)

- (2014) The use of Titanium Clips Markers to monitor the position of GE junction using simple fluoroscopy

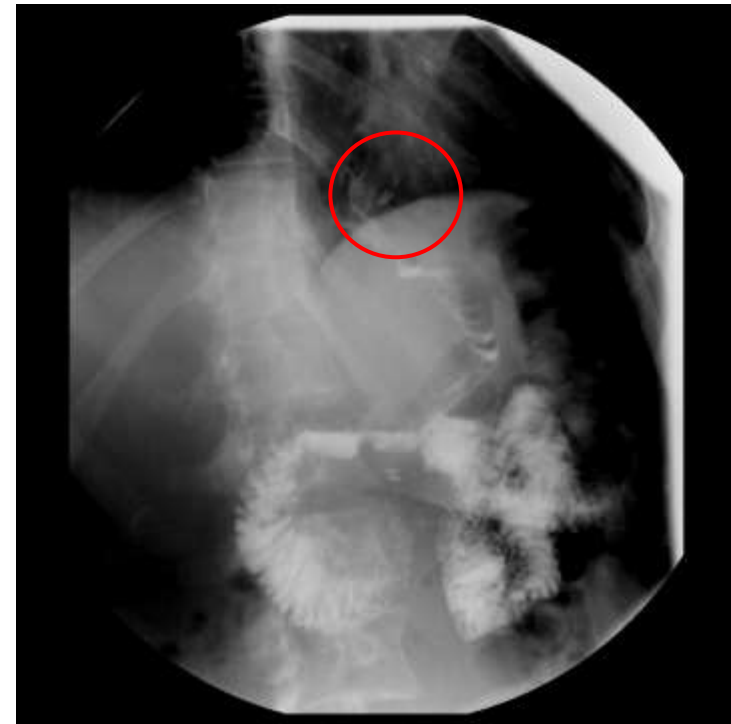


# R-PEL – Surgical Protocols (PAH)

- (2014) The use of **Titanium Clips Markers** to monitor the position of upper part of the stapled line & GE junction by using simple fluoroscopy



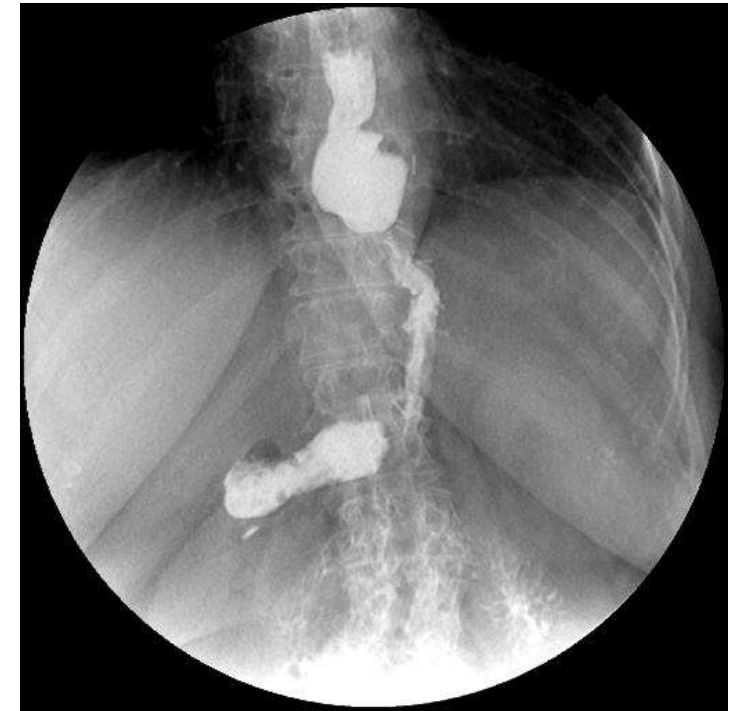Normal /expected image after LSG



The upper part of the LSG is migrated

# R-PEL – Surgical Protocols (PAH)

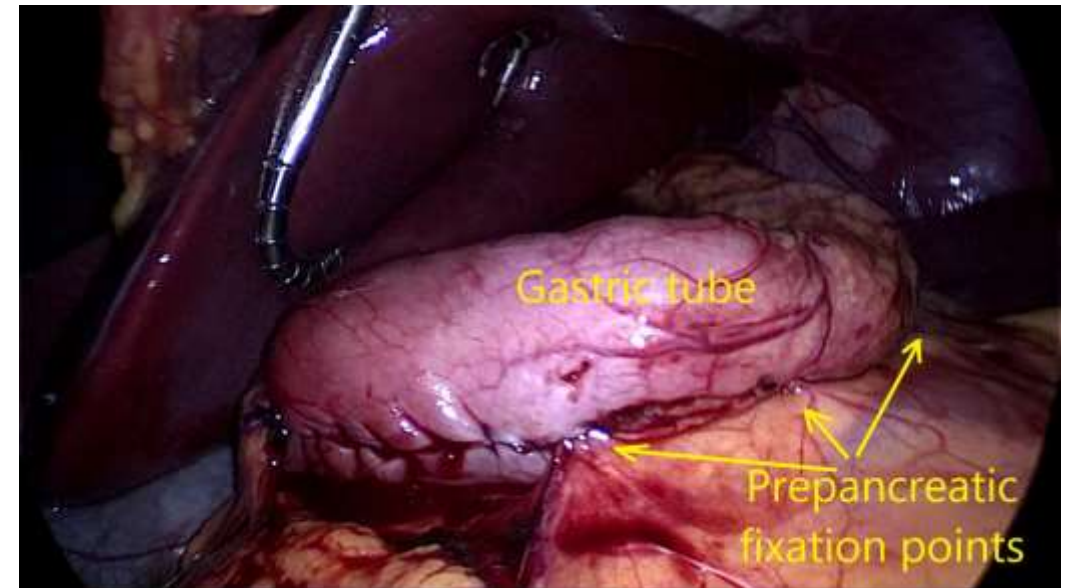
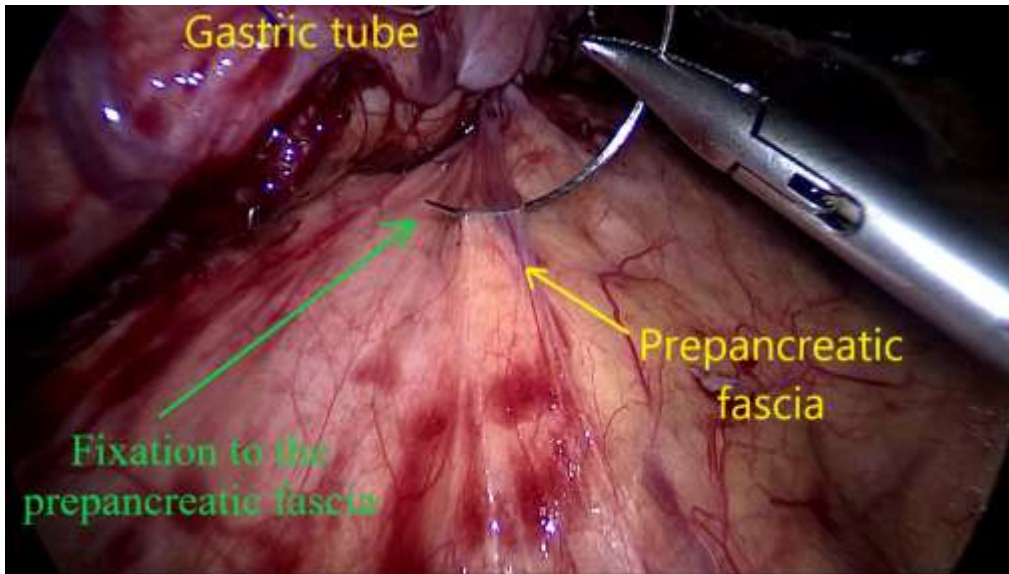
- (2014) – Active search for HH and Cruroraphy (**HHR up to 43%**)
- We observed a high number of **ITM after HHR**
  - Increased number of reoperations (GERD issues)



C.Copaescu et al.,Chirurgia, 2019

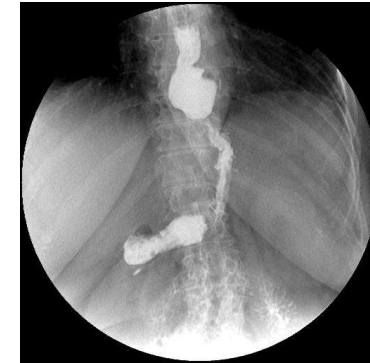# R-PEL – Surgical Protocols (PAH)

- (2015) Protocol of gastric tube fixation to the prepancreatic fascia (**PPF**)
  - to prevent the gastric twist and (may be) the ITM
  - the stapled line is routinely oversewn



# R-PEL – Surgical Protocols (PAH)

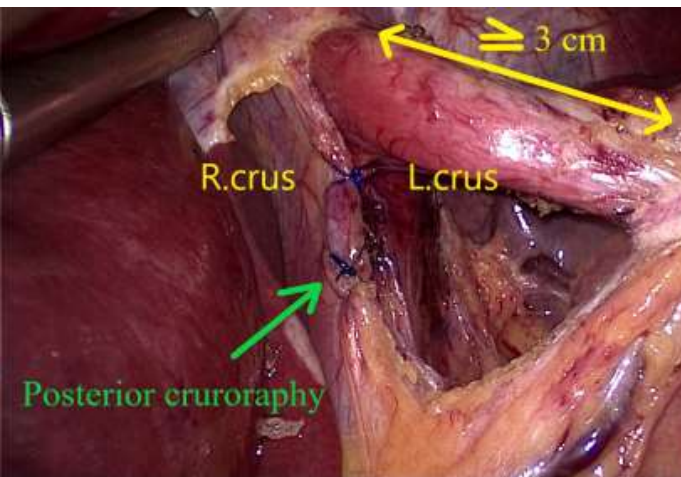
- (2014) – Active search for HH and Cruroraphy (**HHR up to 43%**)
- We observed a high number of **ITM after HHR**
  - Increased number of reoperations (GERD issues)
- (2016) A prospective study including **all the consecutive patients with LSG & HHR & PPF** was started
  - IRB approved and registered in 2015



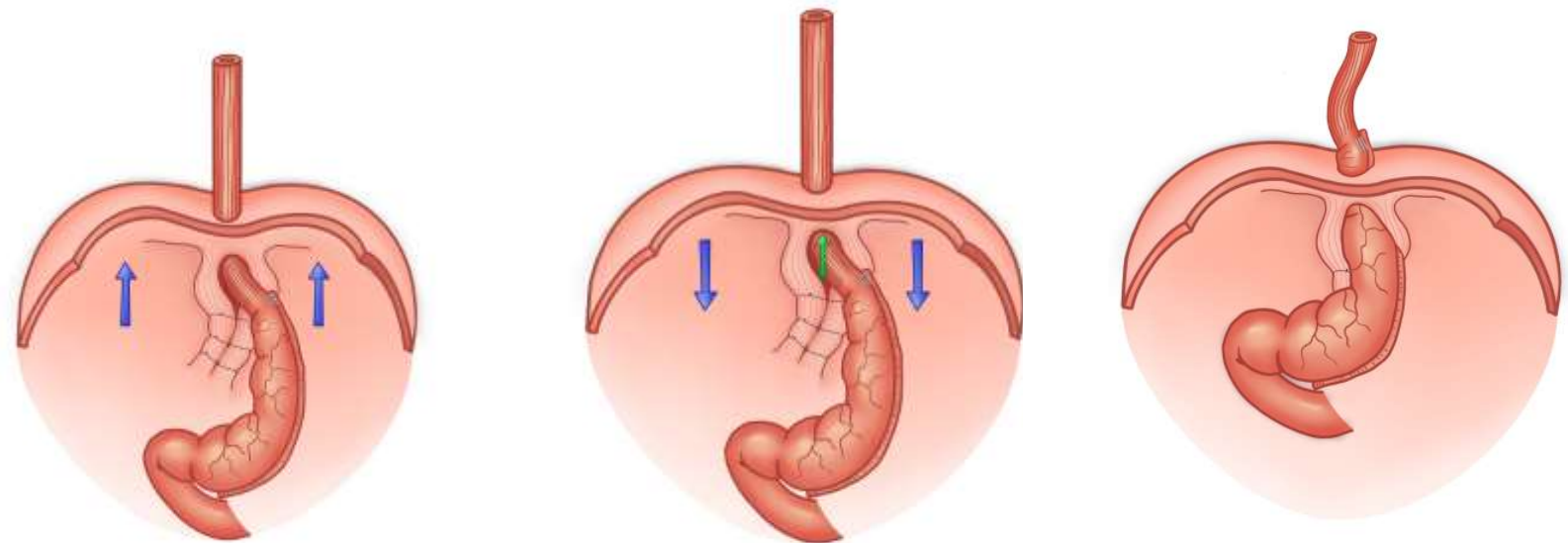


# R-PEL – Surgical Protocols

- 2017 – Noticed a very early po ITM after HHR (alarming!)
  - A Hypothesis for the ITM mechanism

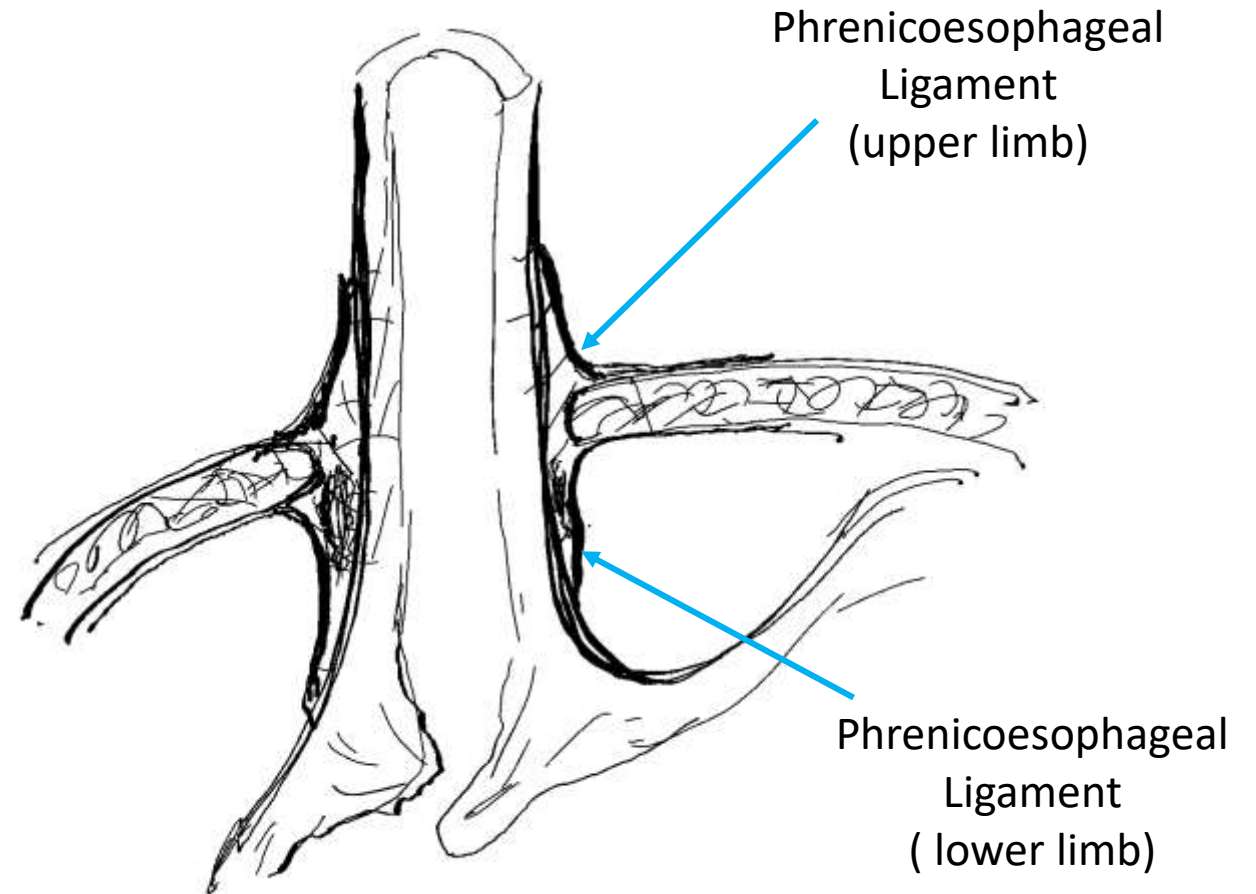
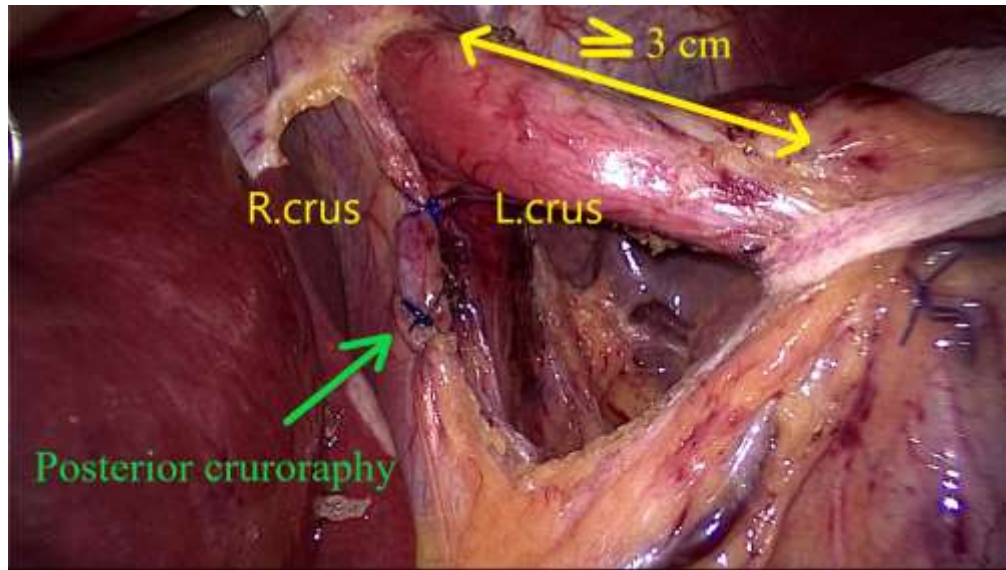


**Intraoperative position of GEJ**  
(the diaphragm is lifted by CO<sub>2</sub>)



**Postoperative position of GEJ**  
Progressive ITM

# Hiatal Hernia Repair Dissection & Cura Approximation



# Reconstruction of Phrenico-Esophageal Ligament Surgical Technique

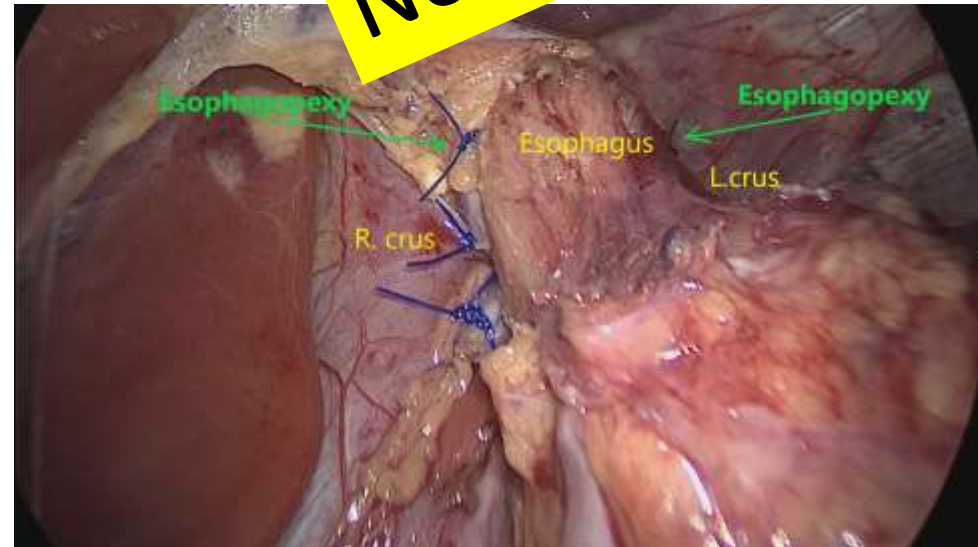
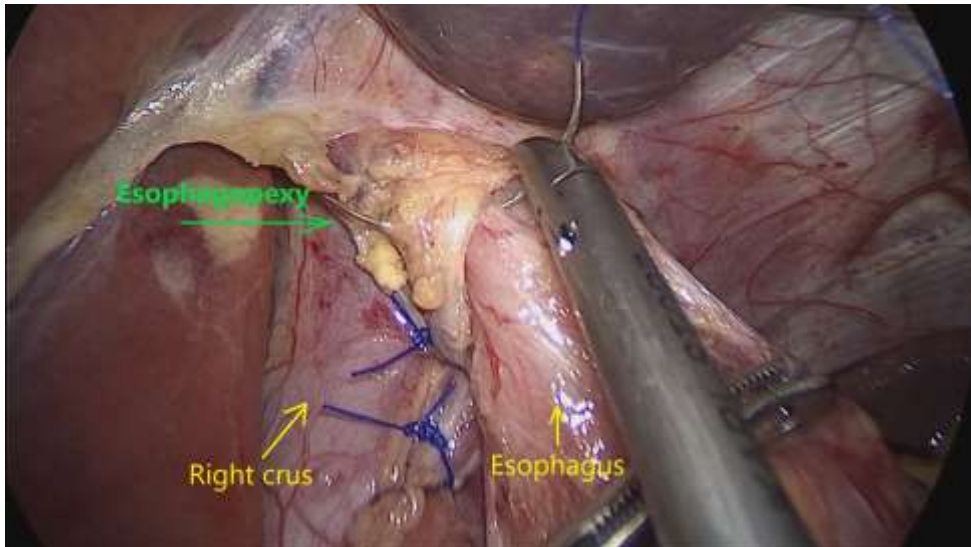
- **2018 – R-PEL**

- Two seromuscular non-resorbable 3.0 stitches are passed on both sides of the esophagus to bond it to the diaphragm (at 9 o'clock and 3 o'clock)

- AIM:

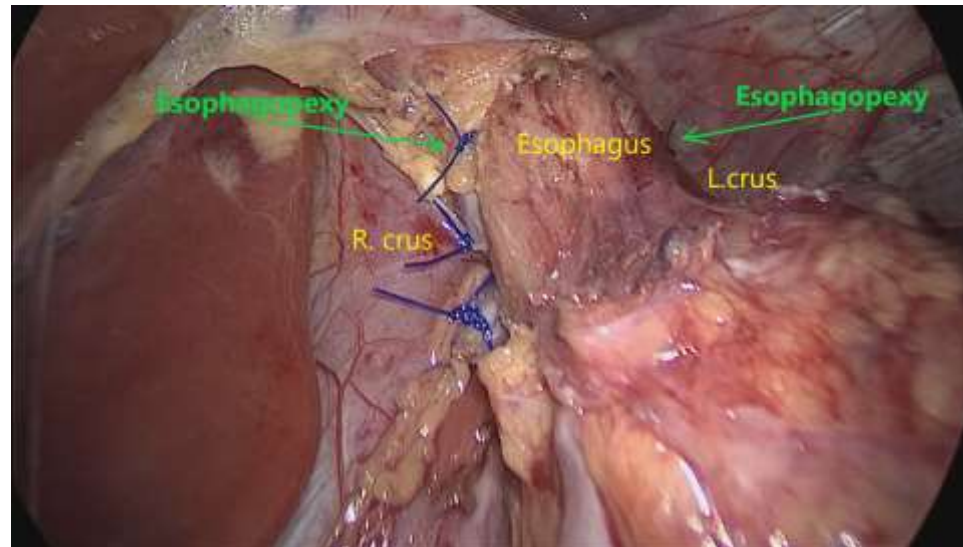
- To maintain the LES & cardia below the diaphragm and,
- To guide the scarring tissue formation as a surrogate for the divided

**Novel Concept**



# Reconstruction of Phrenico-Esophageal Ligament (R-PEL)

- ***The objective*** of the study was extended:
  - *to evaluate the efficiency of R-PEL to prevent ITM after concomitant LSG and HHR*
    - Radiological, endoscopic and clinical

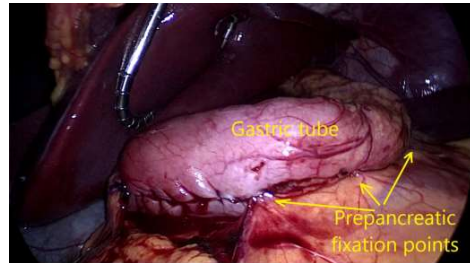


# R-PEL – Study Protocol

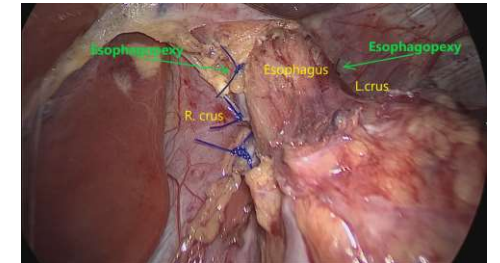
Reconstruction of the phreno-esophageal ligament (R-PEL) prevents the intrathoracic migration (ITM) after concomitant sleeve gastrectomy and hiatal hernia repair

I. Hutopila<sup>1,2</sup> · M. Ciocoiu<sup>3</sup> · L. Paunescu<sup>3</sup> · C. Copaescu<sup>1,4,5</sup>

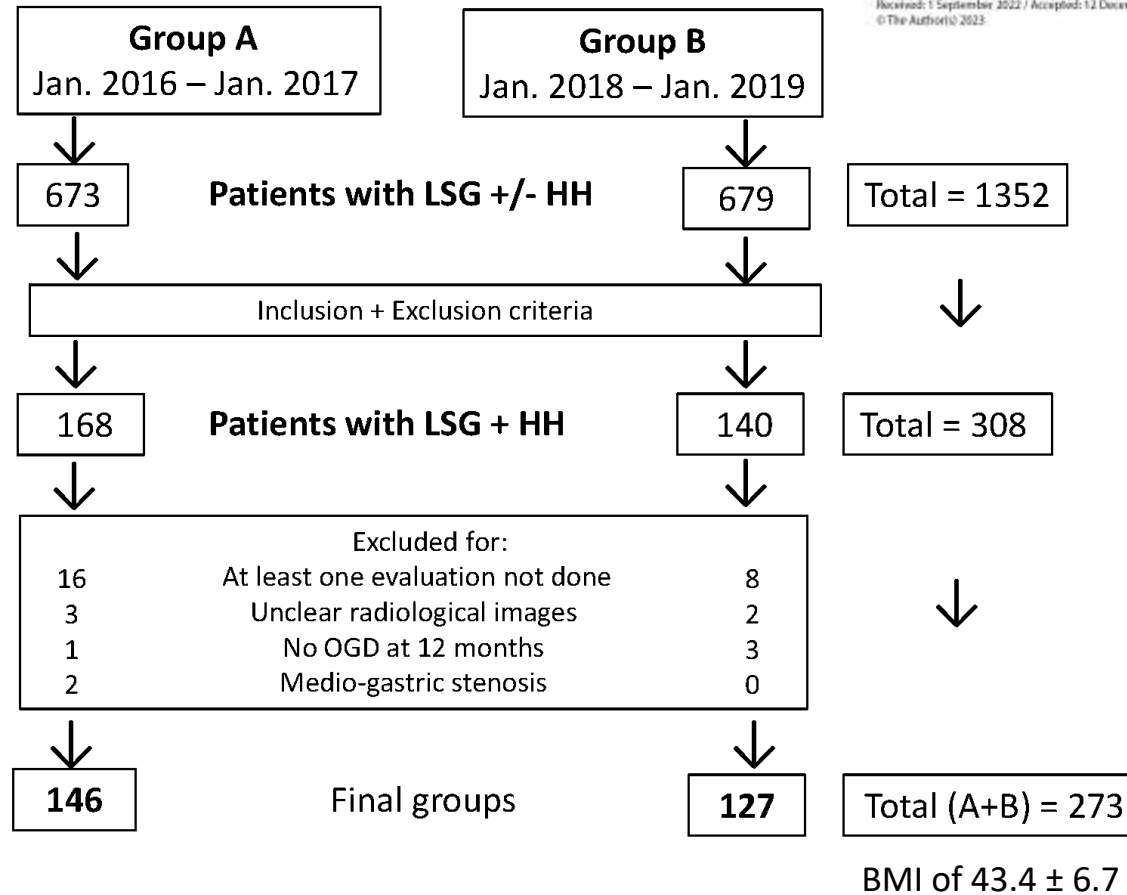
Received: 1 September 2022 / Accepted: 12 December 2022  
 © The Author(s) 2023



**Group A**  
**HHR + PPF**



**Group B**  
**HHR + PPF + R-PEL**



Flowchart for the studied groups.

# R-PEL – Study Protocol

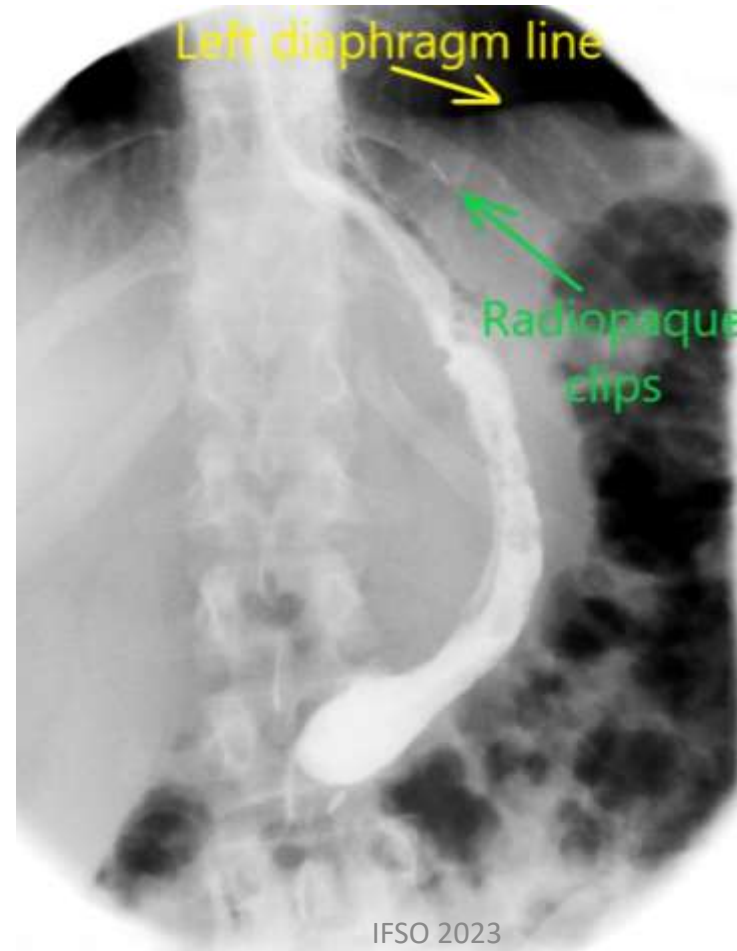
Two radiologist and two surgeons evaluated all the images.

**ITM** > 1cm above the diaphragm

**FU visits:**

Upper GI: 1mo, 3mo,6mo,12month

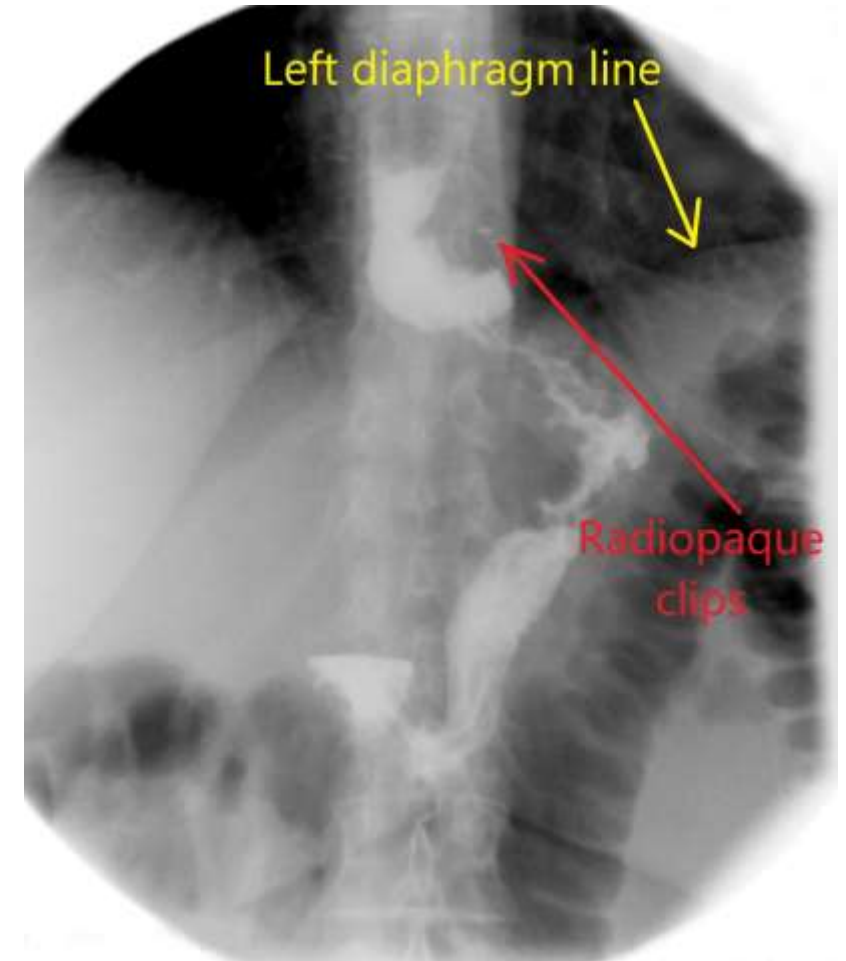
OGD : 12 months



Reconstruction of the phreno-esophageal ligament (R-PEL) prevents the intrathoracic migration (ITM) after concomitant sleeve gastrectomy and hiatal hernia repair

I. Hutopila<sup>1,2</sup> · M. Ciocoiu<sup>3</sup> · L. Paunescu<sup>3</sup> · C. Copescu<sup>1,4,5</sup>

Received: 1 September 2022 / Accepted: 12 December 2022  
© The Author(s) 2023



# R-PEL –1-year Results

Similar metabolic outcomes

**Table 2** Postoperative variables for the study groups

	GroupA (N= 146)	GroupB (N= 127)	P value
ITM			0.01
No	72 (49.3%)	116 (91.3%)	
Yes	74 (50.7%)	11 (8.7%)	
Esophagitis postop 1 year			
No	64 (43.8%)	74 (58.2%)	
Mild (A+B)	77 (52.7%)	52 (41%)	
C	5 (3.4%)	1 (0.8%)	

## Group B (R-PEL) vs Group A

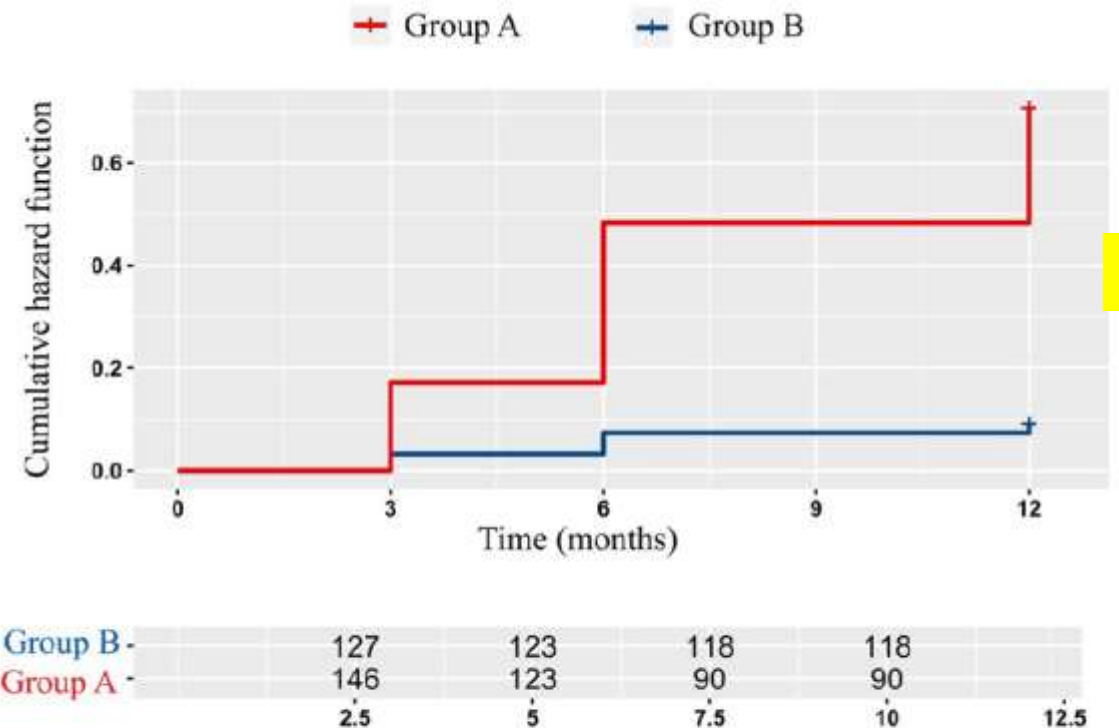
- ITM : 6 times less
- Severe GERD : 5 times less



## Reconstruction of the phreno-esophageal ligament (R-PEL) prevents the intrathoracic migration (ITM) after concomitant sleeve gastrectomy and hiatal hernia repair

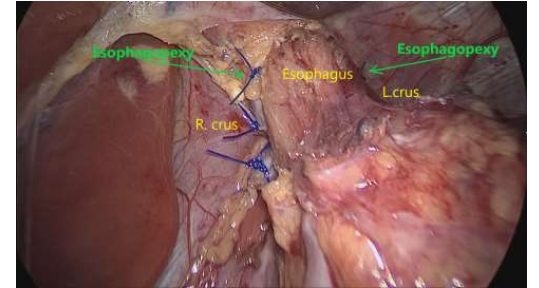
I. Hutopila<sup>1,2</sup> · M. Ciocoiu<sup>3</sup> · L. Paunescu<sup>3</sup> · C. Copaesca<sup>1,4,5</sup>

Received: 1 September 2022 / Accepted: 12 December 2022  
 © The Author(s) 2023



**Fig. 6** Cumulative hazard risk for ITM

# R-PEL –1-year Results



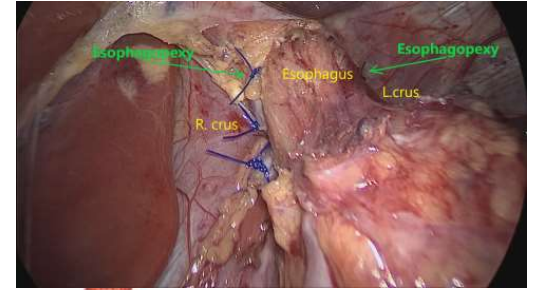
	Group A	Group B	P value	Obs.
Esophageal perforation	-	-		
Esophageal bleeding (in/out)	-	-		
Diaphragmatic bleeding	2	3	NS	Intraoperative, easy to control
Diaphragmatic Laceration	-	-		
Acute IT Migrations	-	-		
Dysphagia	14(9.5%)	13 (10.4%)	NS	Mild, Transitory, within the 1 <sup>st</sup> po week
Nausea & vomiting	22(15%)	18 (14%)	NS	Transitory, within the 1 <sup>st</sup> POD
Gastric Leak	-	-		
Gastric fistula	-	-		
Stapled line bleeding	-	-		No reoperation/no transfusion
Any postoperative bleeding	3	2	NS	Trocar site, hematoma
Stenosis	-	-		Two patients in Group A - excluded
DVT	-	-		
Mortality (90 days)	0	0		
EWL(%) mean (SD)	86.7 (15.6)	86.4 (16.2)	0.87	
GERD complains	54(37%)	27(21.3%)	0.01	Patients' reports
Mild Esophagitis	77 (52.7%)	52 (41%)	0.2	Not audited
Severe Esophagitis	5 (3.4%)	1 (0.8%)	0.01	
Barrett's	-	-		
ITM	72 (50.1%)	11 (8.7%)	0.01	

Additional OR time for R-PEL min 9 (7-13)

IFSO 2023

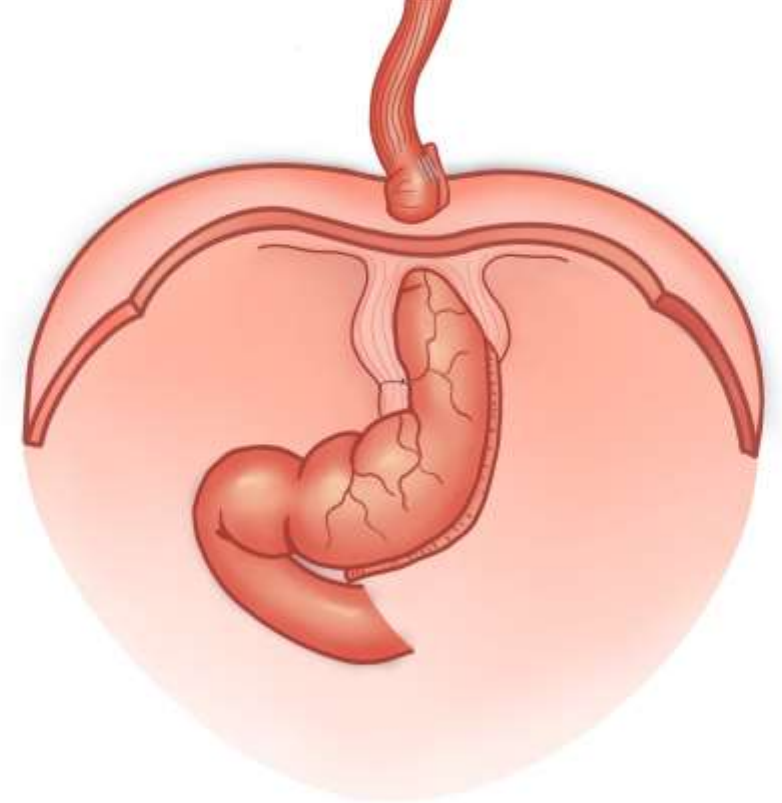Unpublished data

# R-PEL –1-year Results



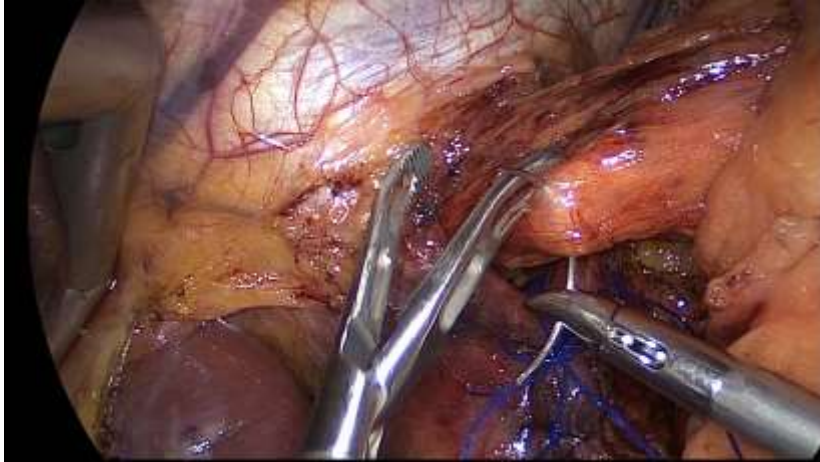
## Analysis of the R-PEL surgical technique

- Possible causes for 8.7% ITM after R-PEL
  - Inconsistent stitches
  - Rupture of the stitches due to vomit?
  - Two points of fixation are not enough to balance the tension?( hypothesis)
- We have decided to modify the technique adding another point of esophagopexy
  - At 2 , 6 and 10 o'clock)

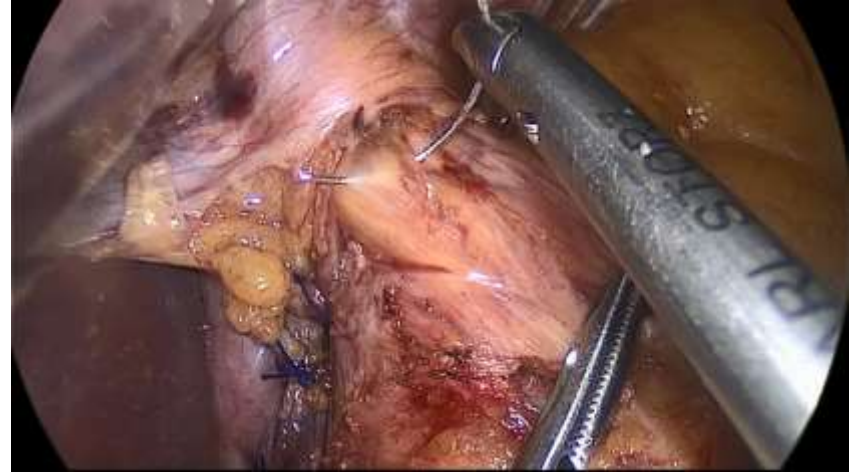

# Reconstruction of Phrenico-Esophageal Ligament (R-PEL – on 3 points – GROUP C)

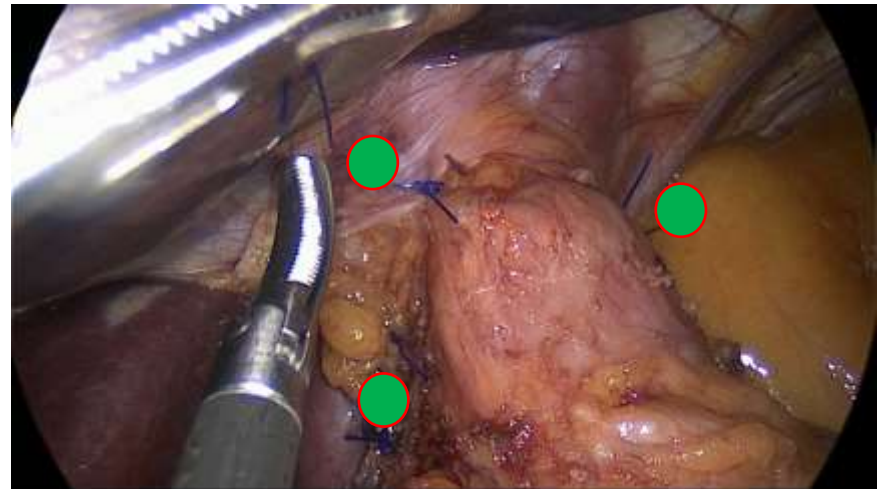
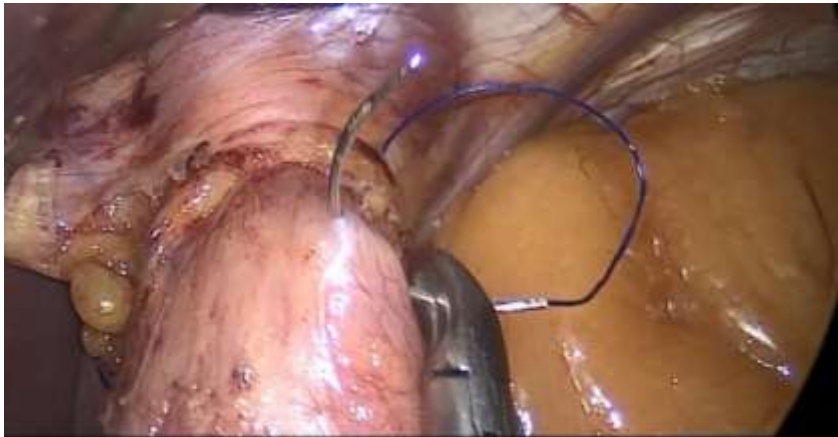6 o'clock



10 o'clock

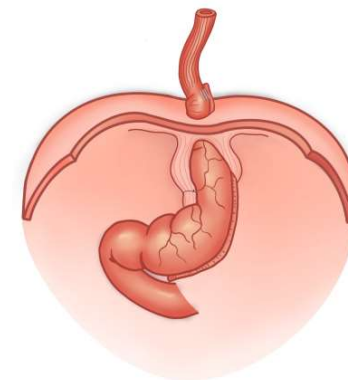

2 o'clock



# Intrathoracic Migration after LSG&HHR<sup>R</sup>

## 3-year Results

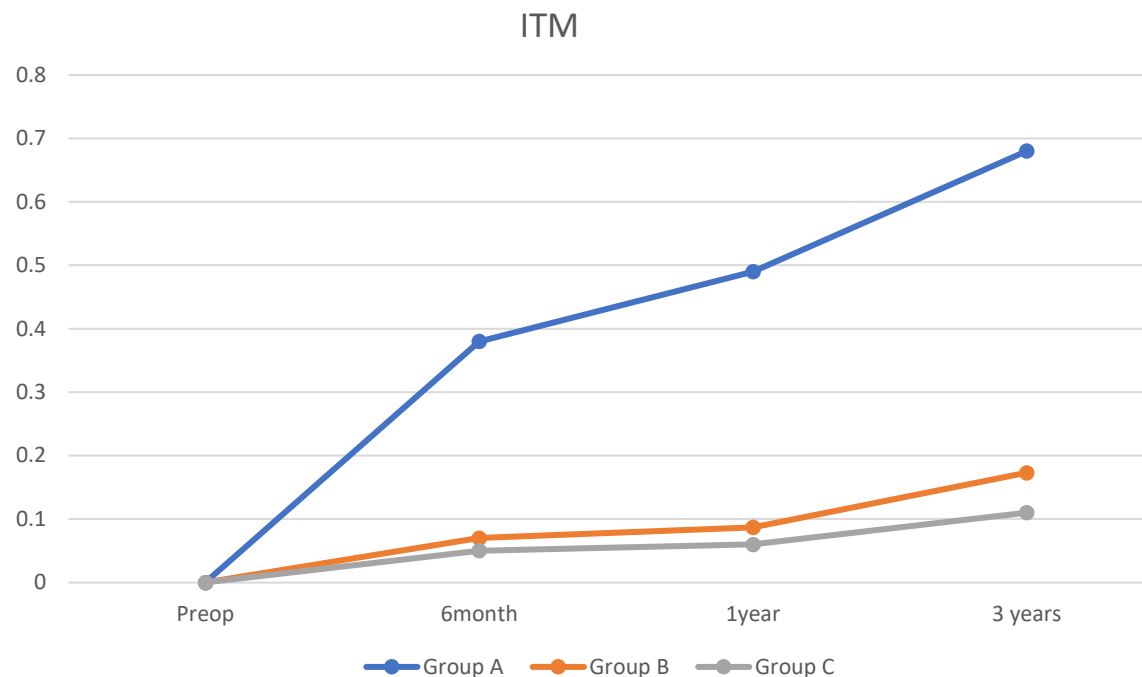


Group A (HHR only) 146pts  
 Group B (R-PEL) 127 pts  
 Group C (R-PEL 3 points) 86pts

FU rate at 1 year : 100%  
 FU rate at 3 years:  
 Groups A,B,C: 82%;85%,79%

Reoperations:  
 Group A 4pts  
 Group B 2 pts,  
 Group C 0 pts

No other related complications added



	Group A	Group B	Group C	P value
ITM 1 year	72 (50.1%)	11 (8.7%)	6 (6.2%)	0.01
ITM 3 years	82 (68.2%)	18 (17.4%)	7 (10.6%)	0.01

# R-PEL

## Efficient to control de ITM

The study demonstrates:

- Significant contribution of R-PEL in preventing the ITM after LSG&HHR
  - 10.6 % (17.4%) vs 68% at 3 years
  - Cumulative hazard risk for ITM at 12 months (11x less with R-PEL)
- Data to compare with:
  - Studies looking radiologically to the efficiency of other BS techniques to control the ITM after LSG & HHR scarce
  - No other study for esophageal fixation after LSG and HHR
- Data to compare with:
  - Nissen Fundoplication - (& HHR) ITM 30% in the first week <sup>1</sup>
  - RYGBP – ITM 67% at 10 year ( CT 3D) <sup>2</sup>

1.Hainaux B, Sattari A, Coppens E, Sadeghi N, Cadiere GB (2002) Intrathoracic migration of the wrap after laparoscopic Nissen fundoplication: radiologic evaluation. AJR Am J Roentgenol 178(4):859–862

2.Arnoldner MA, Felsenreich DM, Langer FB, Weber M, Mang T,Kulinna-Cosentini C et al (2020) Pouch volume and pouch migration after Roux-en-Y gastric bypass: a comparison of gastroscopy and 3 D-CT volumetry: is there a “migration crisis”? Surg Obes Relat Dis 16(12):1902–1908

# R-PEL

## Efficient to control de ITM

- Strong association of ITM control with reducing the severe esophagitis
- Helps to demonstrate that the “sleeve” concept is not refluxogenic
  - the gastric tube migration might be mostly responsible for postoperative “de novo” or unsolved GERD.
- Good safety profile
  - no persistent dysphagia, dilatations, perforations, reoperations related to R-PEL
- R-PEL can be used for HHR & with any bariatric procedure

# Limits of the study

- Radiological finding
  - Need for fluoroscopy (equipment), radiologist / surgeon
  - No MRI/CT scan – study design aimed to be simple
- No 24h pH-metry study to evaluate GERD
  - GERD is a multifactorial disease – hard to compare on clinical data
  - Endoscopy was heterogenous
    - only C esophagitis was considered

# Conclusions

- Concurrent LSG and HHR by crura approximation only has a very high rate of ITM in the first postoperative year
  - 50% at 1 year and 68% at 3 years
- R-PEL proved to be very safe and significantly reduced the rate of postoperative ITM after LSG & HHR.
  - 7 times, on mid-term
  - It lasts significantly better as compared with HHR only
- Data from the study supports the routine use of R-PEL as a simple innovative technique to prevent and control the ITM after concomittant HHR and various bariatric procedures.

# Thank you!



*See you  
in  
Vienna*

**SAVE THE DATE**

[www.ifso-ec2024.com](http://www.ifso-ec2024.com)